

**PATIENT**

Skye Melvin

PRESENTING CLINICAL SIGNS

Mass on neck. Suddenly appeared about 3 days ago

SPECIES

K9

COMPUTED TOMOGRAPHIC STUDY OF THE NECK

Plain and post contrast studies available for review.

BREEDSpringer
Spaniel/Labradoodle**COMPUTED TOMOGRAPHIC FINDINGS**

Cavitation and severe enlargement of the right retropharyngeal lymph node are noted. The lymph node measures approximately 10 cm in length and 5 cm in diameter. Multifocal internal cavitation with fluid filled, contrast filled areas is noted as well as severe peripheral soft tissue swelling with fat stranding and increased contrast enhancement. Fat stranding and soft tissue swelling are accentuated ventral to the lymph node. No foreign material is seen.

SEX

F

The left retropharyngeal and bilateral submandibular lymph nodes present moderate symmetric enlargement.

The tonsils are enlarged and everted.

AGE

25 Weeks

COMPUTED TOMOGRAPHIC DIAGNOSIS

- Severe cavitating enlargement of the right retropharyngeal lymph node compatible with abscessation.
- Moderate generalized regional lymphadenitis and peripheral cellulitis.
- Tonsilitis.

INTERPRETED BYNele Eley, DVM
Dr. med. Vet. DipECVDI**INTERPRETATION OF THE FINDINGS & FURTHER RECOMMENDATIONS**

The CT findings are compatible with abscessation of the right retropharyngeal lymph node. Ruptured abscess or translocation of septic material into the periphery is thought likely. Extensive peripheral cellulitis is noted as well as regional lymphadenitis and tonsilitis. Foreign material is not seen even though foreign material related origin cannot be ruled out entirely. Small organic pieces of foreign material may not be seen on CT. Drainage of the lymph node abscess should be discussed versus en bloc resection/excision of the lymph node.

HOSPITAL NAMEBlairstown Animal
Hospital**REFERRING VET**

Dr. Summers

INVOICE

54992

DATE

11-4-22



PATIENT

Skye Melvin

SPECIES

K9

BREED

Springer
Spaniel/Labradoodle

SEX

F

AGE

25 Weeks

INTERPRETED BY

Nele Eley, DVM
Dr. med. Vet. DipECVDI

HOSPITAL NAME

Blairstown Animal
Hospital

REFERRING VET

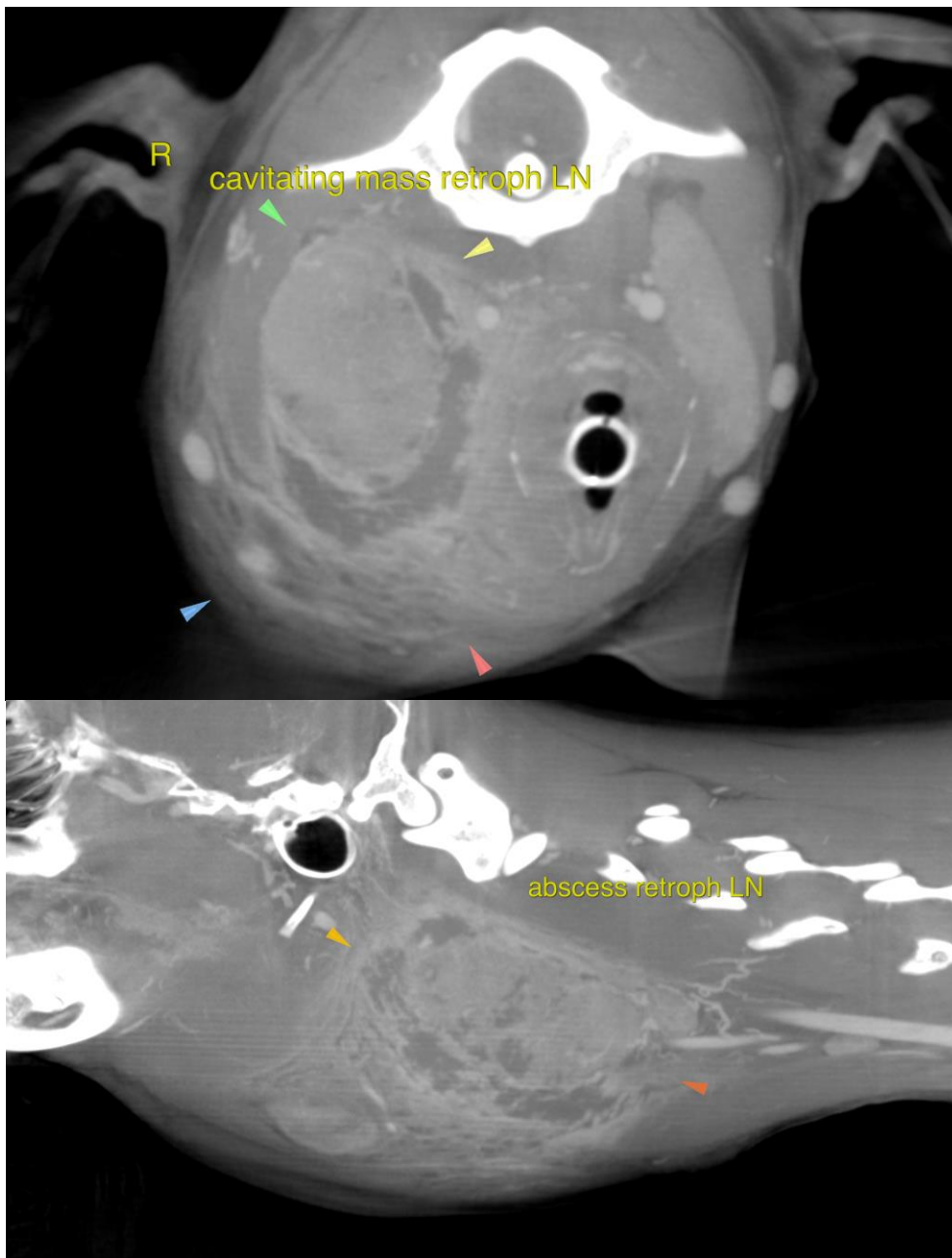
Dr. Summers

INVOICE

54992

DATE

11-4-22





PATIENT

Skye Melvin

The information and recommendations provided are based on the images presented by the referring veterinarian/sonographer. No evaluation can be communicated regarding pathology that was not visible in the image/video clips provided.

Thank you for this referral. If the clinical or image interpretation does not parallel your findings or if I can be of any further assistance please contact me.

SPECIES

K9

Nele Eley, DVM, Dr. med. vet., DipECVDI
European Specialist in Veterinary Diagnostic Imaging, Cert. Radiology,
Senior lecturer University of Giessen, Germany, Veterinary Faculty, Department of Radiology
Nele.Eley@sonopath.com

BREED

Springer
Spaniel/Labradoodle

SEX

F

AGE

25 Weeks

INTERPRETED BY

Nele Eley, DVM
Dr. med. Vet. DipECVDI

HOSPITAL NAME

Blairstown Animal
Hospital

REFERRING VET

Dr. Summers

INVOICE

54992

DATE

11-4-22