



PATIENT

Carina Rodriguez

PRESENTING CLINICAL SIGNS

Patient has presented to this study with paraplegia in 4 limbs owner noted since last Saturday, back pain is present for anesthesia induction.
Abnormal PE/Chem/CBC/UA Results: CBC --- unremarkable CHEM --- BUN mild decreased, TP and GLOB mild increased, CHOL and AMYL mild decreased Snap 4dx --- EC-EE: positive

SPECIES

Canine

COMPUTED TOMOGRAPHIC STUDY OF THE CERVICAL, THORACIC, & LUMBAR SPINE

Plain and post IV contrast studies available for review.

BREED

Dachshund

COMPUTED TOMOGRAPHIC FINDINGS

The vertebral count is normal in all segments of the spine.

SEX

SF

Multifocal chondroid disc degeneration is seen.

There is mild intervertebral disc space narrowing at T11/12. A moderate amount of mineralized intervertebral disc material is extruded into the right and dorsal epidural space. Right sided neuroforaminal extension of the extrusion is noted as well as mild cranial migration of the material. Moderate leftward and ventral deviation and compression of the spinal cord are seen.

AGE

8 Years

There is a mild intervertebral disc protrusion between T12 and T13 and between L7 and S1.

INTERPRETED BY

Nele Eley, DVM
Dr. med. Vet. DipECVDI

COMPUTED TOMOGRAPHIC DIAGNOSIS

- Moderately compressive right sided intervertebral disc extrusion T11/12 with neuroforaminal extension.
- Multifocal chondroid disc degeneration.
- T12/13 and L7/S1 mild intervertebral disc protrusions.

HOSPITAL NAME

Veterinary Image
Center

INTERPRETATION OF THE FINDINGS & FURTHER RECOMMENDATIONS

The clinical signs can be explained by the intervertebral disc protrusion within the caudal thoracic spine between T11 and T12. Note the right sided position of the extrusion with mild migration and extensive neuroforaminal extension. Surgical decompression could be considered if not performed already depending on the clinical context.

REFERRING VET

Dr. J. Colon, DVM

INVOICE

54972

DATE

11-4-22



PATIENT

Carina Rodriguez

SPECIES

Canine

BREED

Dachshund

SEX

SF

AGE

8 Years

INTERPRETED BY

Nele Eley, DVM
Dr. med. Vet. DipECVDI

HOSPITAL NAME

Veterinary Image
Center

REFERRING VET

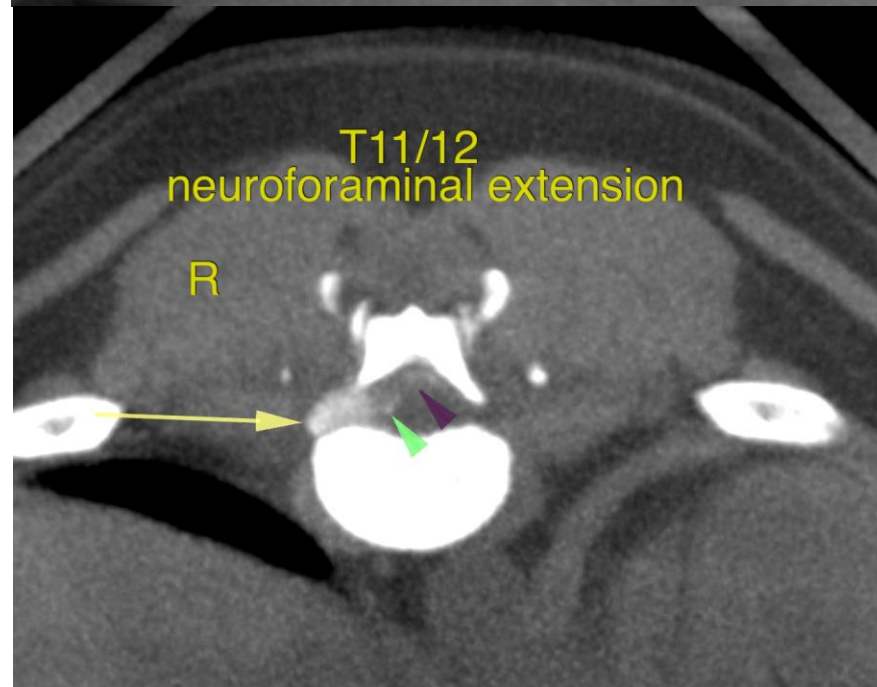
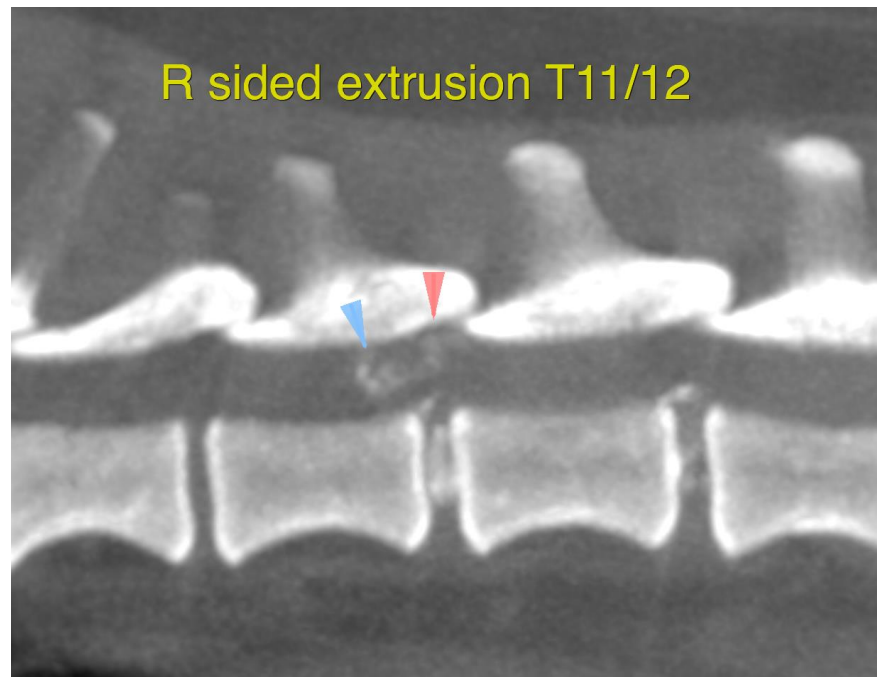
Dr. J. Colon, DVM

INVOICE

54972

DATE

11-4-22





PATIENT

Carina Rodriguez

The information and recommendations provided are based on the images presented by the referring veterinarian/sonographer. No evaluation can be communicated regarding pathology that was not visible in the image/video clips provided.

Thank you for this referral. If the clinical or image interpretation does not parallel your findings or if I can be of any further assistance please contact me.

SPECIES

Canine

Nele Eley, DVM, Dr. med. vet., DipECVDI
European Specialist in Veterinary Diagnostic Imaging, Cert. Radiology,
Senior lecturer University of Giessen, Germany, Veterinary Faculty, Department of Radiology
Nele.Eley@sonopath.com

BREED

Dachshund

SEX

SF

AGE

8 Years

INTERPRETED BY

Nele Eley, DVM
Dr. med. Vet. DipECVDI

HOSPITAL NAME

Veterinary Image
Center

REFERRING VET

Dr. J. Colon, DVM

INVOICE

54972

DATE

11-4-22