



PATIENT

Serci Rodriguez

PRESENTING CLINICAL SIGNS

hard swelling on right side of skull above eye. O noted at some point in October but unsure of exact date. P not bothered by it, non-painful.

SPECIES

Canine

RADIOGRAPHIC STUDY OF THE SKULL

Lateral, dorsoventral, and rostrocaudal views of the skull totaling 4 images available for review.

BREED

Doberman

RADIOGRAPHIC FINDINGS

Moderate smooth thickening of the external lamina of the right frontal sinus is seen. The dorsal contour of the right frontal sinus is more convex than the contour of the left frontal sinus. The osseous lining appears to be intact. Outer and inner layers are smooth, and the frontal sinuses appear to be aerated. No evidence of increased opacity of the frontal sinus and no evidence of regional soft tissue swelling is noted. The nasal cavities present within normal limits. The nasal turbinates are well delineated and separated by evenly spaced gas opacities. The nasal septum is intact.

SEX

Female

RADIOGRAPHIC DIAGNOSIS

- Frontal sinus asymmetry with dorsal deviation and smooth thickening of the external lamina of the right frontal sinus.

AGE

5 Months

INTERPRETATION OF THE FINDINGS & FURTHER RECOMMENDATIONS

The radiographic study reveals hyperostosis and asymmetry of the right frontal sinus with no evidence of concurrent soft tissue changes and a regularly aerated sinus. Congenital malformation and healed/healing fracture after traumatic osseous injury are primary differential diagnoses. Juvenile calvarial hyperostosis and hyperostosis with sinusitis are theoretical but by far less likely differential diagnoses based on the normal appearance of the nasal cavities, normal frontal sinus content, and lack of regional soft tissue swelling.

INTERPRETED BY

Nele Eley, DVM
Dr. med. Vet. DipECVDI

HOSPITAL NAME

The Pet Hospital of
Stratford

REFERRING VET

Dr. Claudia Giuliani

INVOICE

55476

DATE

11-30-22



PATIENT

Serci Rodriguez

SPECIES

Canine

BREED

Doberman

SEX

Female

AGE

5 Months

INTERPRETED BY

Nele Eley, DVM
Dr. med. Vet. DipECVDI

HOSPITAL NAME

The Pet Hospital of
Stratford

REFERRING VET

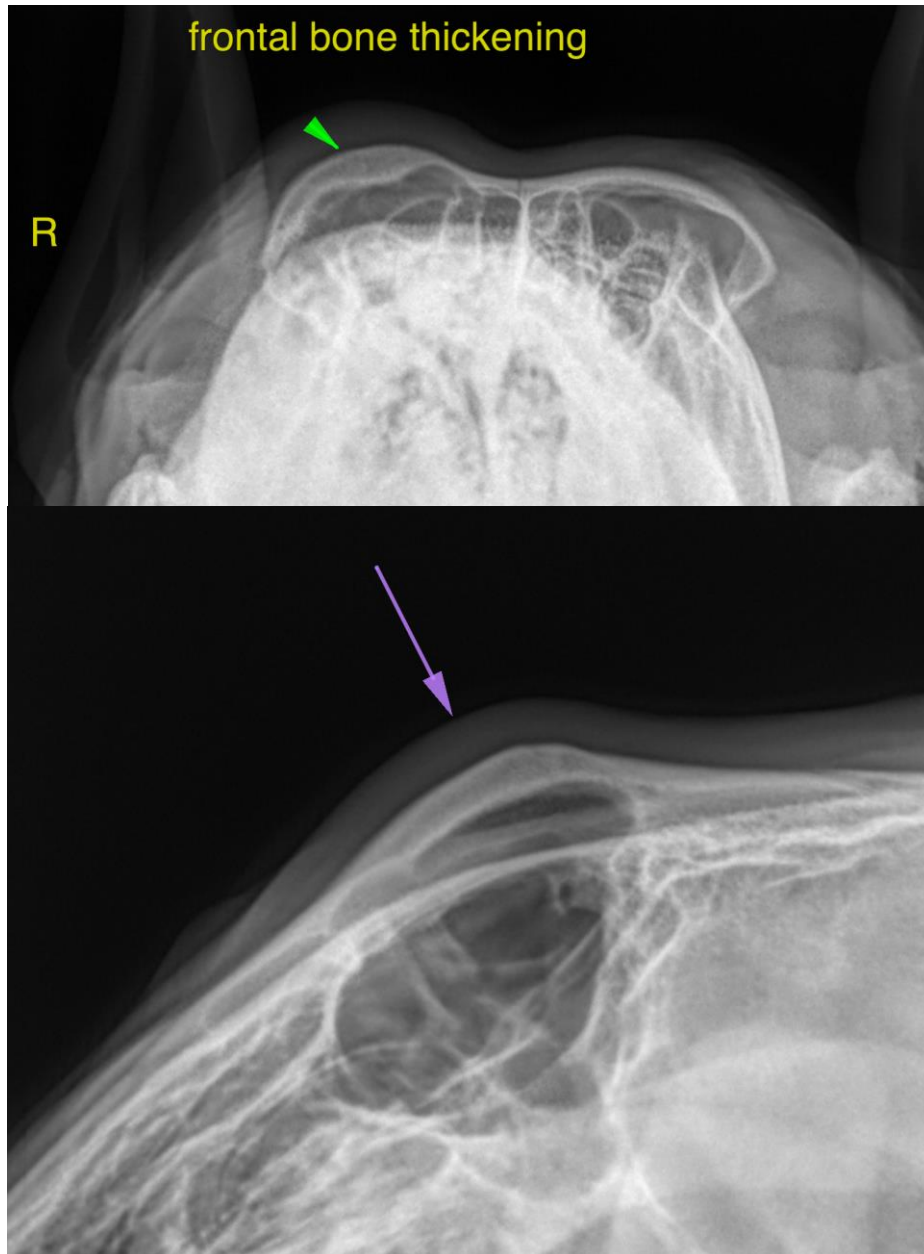
Dr. Claudia Giuliani

INVOICE

55476

DATE

11-30-22





PATIENT

Serci Rodriguez

The information and recommendations provided are based on the images presented by the referring veterinarian/sonographer. No evaluation can be communicated regarding pathology that was not visible in the image/video clips provided.

Thank you for this referral. If the clinical or image interpretation does not parallel your findings or if I can be of any further assistance please contact me.

SPECIES

Canine

Nele Eley, DVM, Dr. med. vet., DipECVDI
European Specialist in Veterinary Diagnostic Imaging, Cert. Radiology,
Senior lecturer University of Giessen, Germany, Veterinary Faculty, Department of Radiology
Nele.Eley@sonopath.com

BREED

Doberman

SEX

Female

AGE

5 Months

INTERPRETED BY

Nele Eley, DVM
Dr. med. Vet. DipECVDI

HOSPITAL NAME

The Pet Hospital of
Stratford

REFERRING VET

Dr. Claudia Giuliani

INVOICE

55476

DATE

11-30-22