



**PATIENT**

Nash McDonald

**PRESENTING CLINICAL SIGNS**

Cardiac Murmur and C+; Echo Performed on 11/30/22

**SPECIES**

Canine

**RADIOGRAPHIC STUDY OF THE THORAX**

Right/left lateral and ventrodorsal views of the thorax totaling 3 images available for review.

**BREED**

Beagle Mix

**RADIOGRAPHIC FINDINGS**

Size and shape of the cardiac silhouette present within normal limits. There is no evidence of specific chamber enlargement. The vertebral heart score is 10.5 which is within the reference range. No evidence of pulmonary vessel dilation is seen. There is no evidence of congestive heart failure.

**SEX**

Male Neutered

Sternal contact and position of the trachea bifurcation present within normal limits. Course and width of the trachea present within normal limits.

**AGE**

11

There is a moderate generalized bronchial lung pattern with even distribution throughout the lung and occasional mild peribronchial cuffing. Age related incidental pulmonary osteomas are seen.

No evidence of mediastinal widening is noted.

The thoracic boundaries present within age related normal limits.

**INTERPRETED BY**

Nele Eley, DVM  
Dr. med. Vet. DipECVDI

**RADIOGRAPHIC DIAGNOSIS**

- Normal radiographic presentation of the cardiac silhouette.
- Moderate generalized bronchial lung pattern.

**HOSPITAL NAME**

Summit Dog & Cat  
Hospital

**INTERPRETATION OF THE FINDINGS & FURTHER RECOMMENDATIONS**

The radiographic presentation of the cardiac silhouette is within normal limits. There are no signs of congestive heart failure.

**REFERRING VET**

Vogler

A moderate generalized bronchial lung pattern is noted which may be due to chronic allergic/eosinophilic bronchopneumopathy or infectious bronchitis such as viral, bacterial, or parasitic. Further definition by means of airway endoscopy with airway sampling could be discussed versus a clinical trial of empirical management for bronchitis.

**INVOICE**

55488

**DATE**

11-30-22



**PATIENT**

Nash McDonald

**SPECIES**

Canine

**BREED**

Beagle Mix

**SEX**

Male Neutered

**AGE**

11

**INTERPRETED BY**

Nele Eley, DVM  
Dr. med. Vet. DipECVDI

**HOSPITAL NAME**

Summit Dog & Cat  
Hospital

**REFERRING VET**

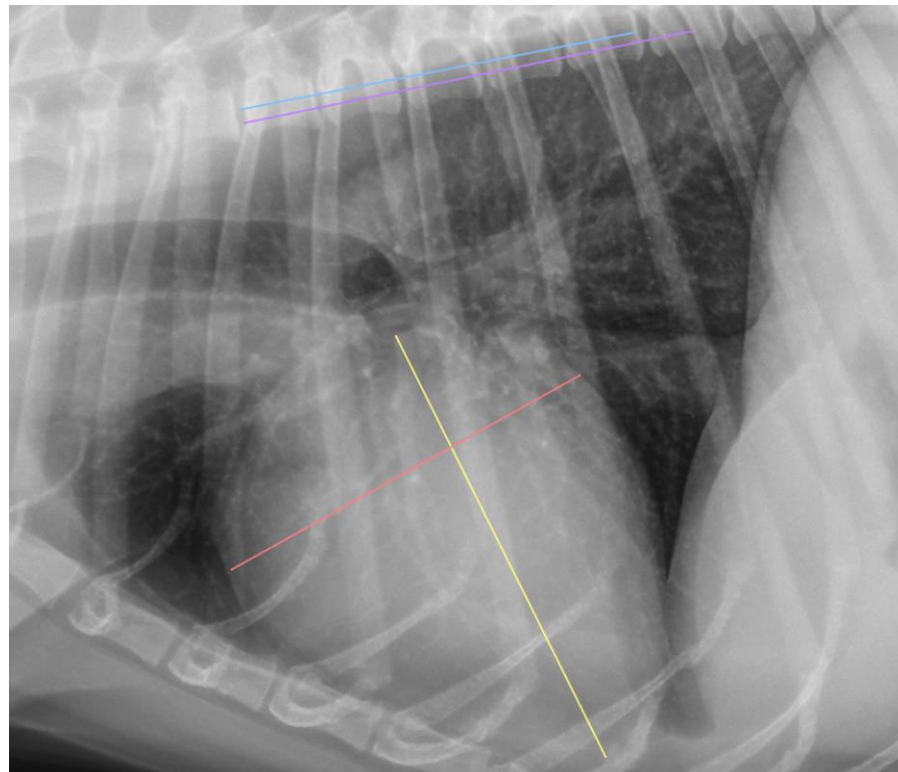
Vogler

**INVOICE**

55488

**DATE**

11-30-22



**The information and recommendations provided are based on the images presented by the referring veterinarian/sonographer. No evaluation can be communicated regarding pathology that was not visible in the image/video clips provided.**

Thank you for this referral. If the clinical or image interpretation does not parallel your findings or if I can be of any further assistance please contact me.

**Nele Eley**, DVM, Dr. med. vet., DipECVDI  
European Specialist in Veterinary Diagnostic Imaging, Cert. Radiology,  
Senior lecturer University of Giessen, Germany, Veterinary Faculty, Department of Radiology  
Nele.Eley@sonopath.com