



PATIENT

Marlo Dipreta

PRESENTING CLINICAL SIGNS

Pt presented for a dry, hacking cough that started about a month ago. Doesn't happen all the time, but notices it more when pt more active. No discharge from eyes or nose, no vomit/diarrhea. Pt did gain ~11lbs since previous visit in 2019.

SPECIES

Feline

RADIOGRAPHIC STUDY OF THE THORAX

Right/left lateral and dorsoventral views totaling 3 images available for review.

BREED

DSH

RADIOGRAPHIC FINDINGS

The patient is obese.

Abundance of retrosternal and pericardial fat is noted.

SEX

NM

The degree of pulmonary inflation is moderate. A moderate generalized bronchial lung pattern is noted and evenly distributed throughout the lung. Occasional plate like atelectasis and tree-in-bud appearance is seen.

AGE

4.5 Years

There is no radiographic evidence of cardiovascular pathology. The vertebral heart score is 7.5.

Course and width of the trachea are considered within normal limits.

The thoracic boundaries are within normal limits.

INTERPRETED BY

Nele Eley, DVM
Dr. med. Vet. DipECVDI

RADIOGRAPHIC DIAGNOSIS

- Moderate generalized bronchial lung pattern.

HOSPITAL NAME

The Pet Hospital of
Stratford

INTERPRETATION OF THE FINDINGS & FURTHER RECOMMENDATIONS

The radiographic study of the thorax reveals a moderate generalized bronchial lung pattern. Feline allergic lower airway syndrome is a primary differential diagnosis based on the clinical history of the patient and radiographic changes. Infectious bronchitis including viral, bacterial, parasitic, and protozoal cannot be ruled out as a potential differential diagnosis.

REFERRING VET

Dr. Giuliani

INVOICE

55428

DATE

11-29-22



PATIENT

Marlo Dipreta

SPECIES

Feline

BREED

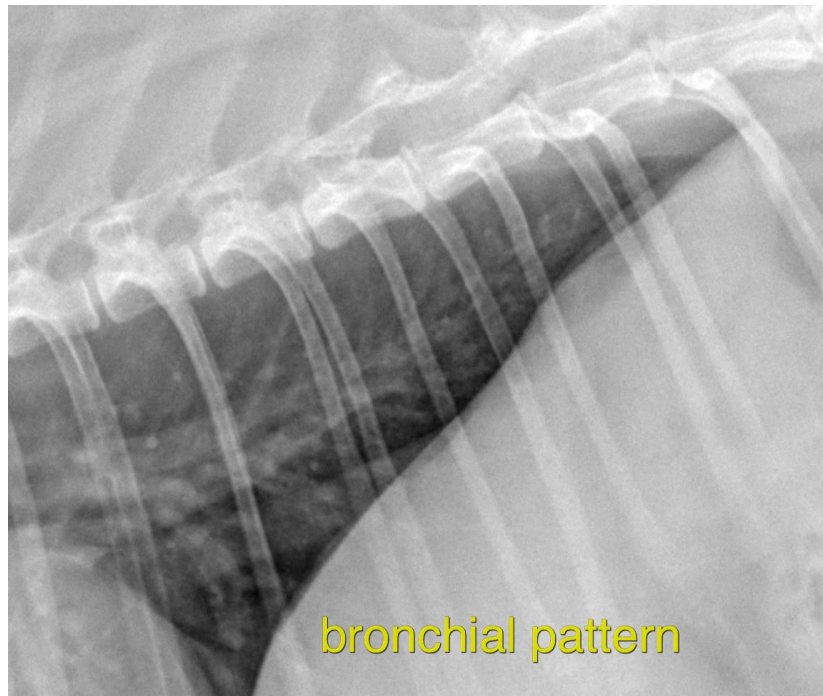
DSH

SEX

NM

AGE

4.5 Years



INTERPRETED BY

Nele Eley, DVM
Dr. med. Vet. DipECVDI

The information and recommendations provided are based on the images presented by the referring veterinarian/sonographer. No evaluation can be communicated regarding pathology that was not visible in the image/video clips provided.

HOSPITAL NAME

The Pet Hospital of
Stratford

Thank you for this referral. If the clinical or image interpretation does not parallel your findings or if I can be of any further assistance please contact me.

Nele Eley, DVM, Dr. med. vet., DipECVDI
European Specialist in Veterinary Diagnostic Imaging, Cert. Radiology,
Senior lecturer University of Giessen, Germany, Veterinary Faculty, Department of Radiology
Nele.Eley@sonopath.com

REFERRING VET

Dr. Giuliani

INVOICE

55428

DATE

11-29-22