



PATIENT PRESENTING CLINICAL SIGNS

Cowboy Hicks
SPECIES Canine
 Abnormal PE/Chem/CBC/UA Results: cough with palpation of the trachea. dental disease

RADIOGRAPHIC STUDY OF THE THORAX

Australian Shepherd Mini
 Right/left lateral and ventrodorsal views of the thorax totaling 3 images available for review.

RADIOGRAPHIC FINDINGS

SEX MN
 The degree of pulmonary inflation is moderate. A moderate generalized bronchial lung pattern with mild peribronchial cuffing and mild diffuse increased in interstitial background opacity is seen.

Course and width of the trachea are considered within normal limits.

AGE There is no evidence of mediastinal widening.

17 Years, 6 Months
 Minimal esophageal aerophagia is seen and considered incidental.

INTERPRETED BY The vertebral heart score is 10. No specific chamber enlargement or generalized cardiomegaly is noted. The radiographic presentation of the cardiac silhouette is within normal limits.

Nele Eley, DVM
 Dr. med. Vet. DipECVDI
 The thoracic boundaries present within normal limits.

HOSPITAL NAME Note the presence of diffuse enlargement of the liver.

RADIOGRAPHIC DIAGNOSIS

- Moderate chronic bronchial lung pattern.
- Hepatomegaly.

REFERRING VET INTERPRETATION OF THE FINDINGS & FURTHER RECOMMENDATIONS

Kim Allyn, DVM
 The radiographic study suggests presence of chronic lower airway disease such as eosinophilic/allergic bronchopneumopathy or infectious bronchitis including viral bacterial or parasitic. Further definition by means of airway endoscopy with airway sampling could be considered.

INVOICE 55430
 The liver changes may represent vacuolar degeneration, metabolic or endocrine hepatopathy as well as diffuse inflammatory, infectious, or neoplastic infiltrate. Further definition by means of blood chemistry and ultrasound could be considered depending on the clinical correlation.

DATE

11-29-22



PATIENT

Cowboy Hicks

SPECIES

Canine

BREED

Australian Shepherd
Mini

SEX

MN

AGE

17 Years, 6 Months

INTERPRETED BY

Nele Eley, DVM
Dr. med. Vet. DipECVDI

HOSPITAL NAME

Dr Leon Anderson

REFERRING VET

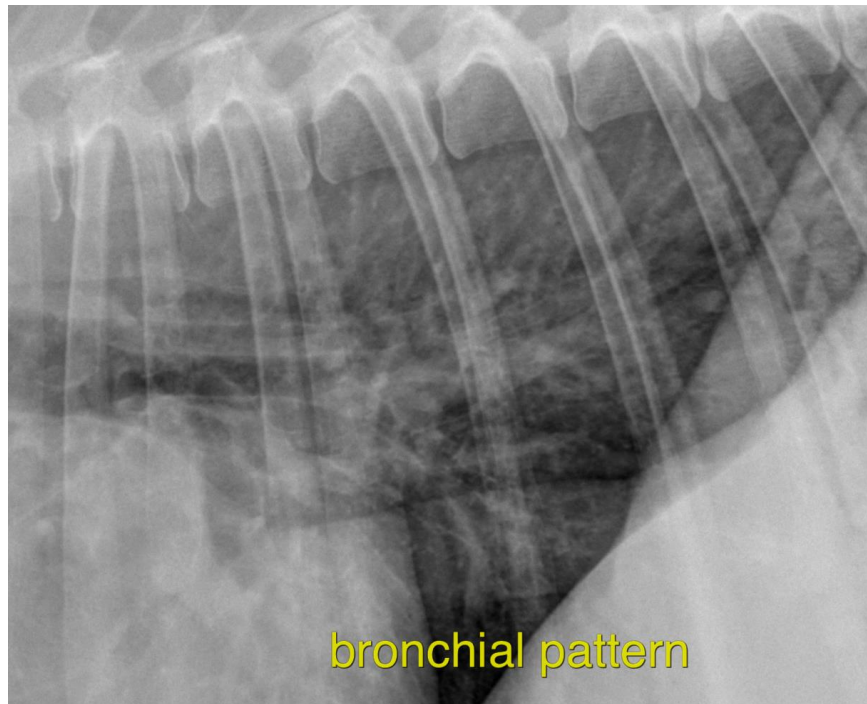
Kim Allyn, DVM

INVOICE

55430

DATE

11-29-22



The information and recommendations provided are based on the images presented by the referring veterinarian/sonographer. No evaluation can be communicated regarding pathology that was not visible in the image/video clips provided.

Thank you for this referral. If the clinical or image interpretation does not parallel your findings or if I can be of any further assistance please contact me.

Nele Eley, DVM, Dr. med. vet., DipECVDI
European Specialist in Veterinary Diagnostic Imaging, Cert. Radiology,
Senior lecturer University of Giessen, Germany, Veterinary Faculty, Department of Radiology
Nele.Eley@sonopath.com