



**PATIENT**

Sadie Austin

**PRESENTING CLINICAL SIGNS**

Seen on emergency in FL (o's second home) with pericardial effusion (hemorrhage)

**SPECIES**

Canine

**COMPUTED TOMOGRAPHIC STUDY OF THE THORAX**

Plain and post contrast studies available for review.

**BREED**

Jack Russell Terrier

**COMPUTED TOMOGRAPHIC FINDINGS**

At the time of the examination, there was no evidence of fluid within the pericardium, mediastinum, or pleural cavities.

**SEX**

FS

The heart presents within normal limits. No evidence of a cardiac or cardiac base mass is seen.

The cranial mediastinal and tracheobronchial lymph nodes present within normal limits. Minimal enlargement of one sternal lymph node at a diameter of 5mm is noted.

**AGE**

8 Years

The visible lung and bronchial tree present within age related normal limits. There is no evidence of pulmonary nodules or masses. Tips of the caudal lung lobes are not fully included.

Course and width of the trachea and bronchial tree present within normal limits.

The thoracic boundaries present within normal limits.

**INTERPRETED BY**

Nele Eley, DVM  
Dr. med. Vet. DipECVDI

**COMPUTED TOMOGRAPHIC DIAGNOSIS**

- Minimal sternal lymphadenomegaly.
- No evidence of pericardial effusion.
- No evidence of a mass at the heart base.

**HOSPITAL NAME**

Advanced Animal  
Imaging

**INTERPRETATION OF THE FINDINGS & FURTHER RECOMMENDATIONS**

The CT findings are within age related normal limits. Minimal enlargement of the sternal lymph node is likely to represent reactive hyperplasia. Early neoplastic infiltrate cannot be ruled out entirely in theory but is considered highly unlikely based on the CT findings.

**REFERRING VET**

Blair Hollowell

There was no evidence of pericardial effusion or heart/heart base mass.

**INVOICE**

55407

**DATE**

11-28-22



**PATIENT**

Sadie Austin

**SPECIES**

Canine

**BREED**

Jack Russell Terrier

**SEX**

FS

**AGE**

8 Years

**INTERPRETED BY**

Nele Eley, DVM  
Dr. med. Vet. DipECVDI

**HOSPITAL NAME**

Advanced Animal  
Imaging

**REFERRING VET**

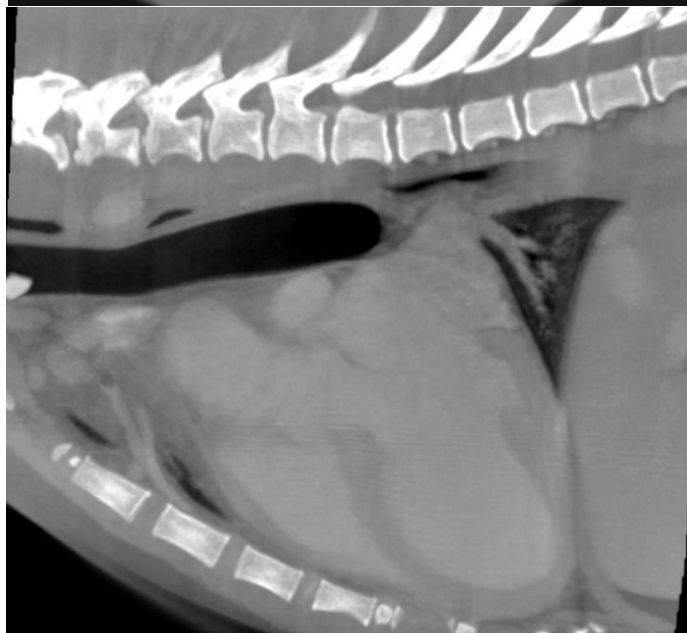
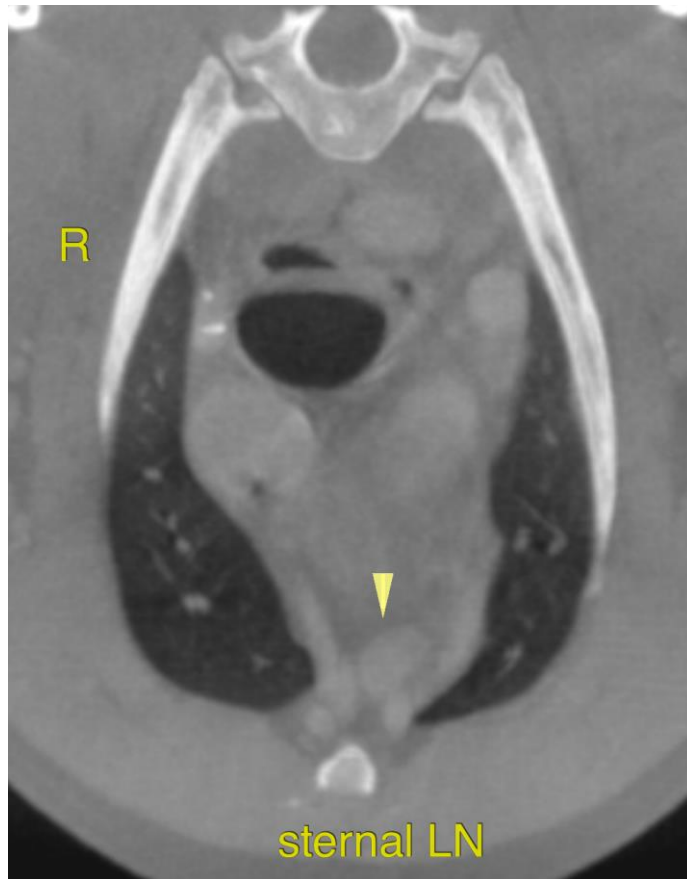Blair Hollowell

**INVOICE**

55407

**DATE**

11-28-22





**PATIENT**

Sadie Austin

The information and recommendations provided are based on the images presented by the referring veterinarian/sonographer. No evaluation can be communicated regarding pathology that was not visible in the image/video clips provided.

**SPECIES**

Canine

Thank you for this referral. If the clinical or image interpretation does not parallel your findings or if I can be of any further assistance please contact me.

**BREED**

Jack Russell Terrier

**Nele Eley**, DVM, Dr. med. vet., DipECVDI  
European Specialist in Veterinary Diagnostic Imaging, Cert. Radiology,  
Senior lecturer University of Giessen, Germany, Veterinary Faculty, Department of Radiology  
Nele.Eley@sonopath.com

**SEX**

FS

**AGE**

8 Years

**INTERPRETED BY**

Nele Eley, DVM  
Dr. med. Vet. DipECVDI

**HOSPITAL NAME**

Advanced Animal  
Imaging

**REFERRING VET**

Blair Hollowell

**INVOICE**

55407

**DATE**

11-28-22