



PATIENT

Baxt Casas

PRESENTING CLINICAL SIGNS

Wheezing and coughing STARTED ~ 10 days ago
Abnormal PE/Chem/CBC/UA Results: N/A

SPECIES

Canine

RADIOGRAPHIC STUDY OF THE THORAX

Right/left lateral and ventrodorsal whole body views totaling 3 images available for review.

Thoracic read requested.

BREED

Terrier Yorkshire mix

RADIOGRAPHIC FINDINGS

The thoracic boundaries present within normal limits.

Course and width of the trachea are considered within normal limits.

SEX

Male

The degree of pulmonary inflation is deep. No abnormal pulmonary opacity is seen. The architecture of the pulmonary interstitium and the bronchial tree present within normal radiographic limits.

AGE

13 Months

The cardiac silhouette presents within normal limits. Baseline vertebral heart score is 9.3.

There is no evidence of abnormal mediastinal widening.

INTERPRETED BY

Nele Eley, DVM
Dr. med. Vet. DipECVDI

RADIOGRAPHIC DIAGNOSIS

- Normal radiographic presentation of the thorax.

INTERPRETATION OF THE FINDINGS & FURTHER RECOMMENDATIONS

No structural bronchopulmonary changes and no evidence of cardiovascular pathology is seen radiographically. It has to be noted though that structural radiographic changes of the lung and bronchial tree typically lag behind the clinical course of inflammatory and infectious diseases. Hence, inflammatory/infectious bronchopneumopathy cannot be ruled out entirely and appears to be one potential differential diagnosis in this patient next to upper respiratory disease.

HOSPITAL NAME

St. Catherine's Animal
Hospital

REFERRING VET

Dr. Boctor

INVOICE

55391

DATE

11-26-22



PATIENT

Baxt Casas

SPECIES

Canine

BREED

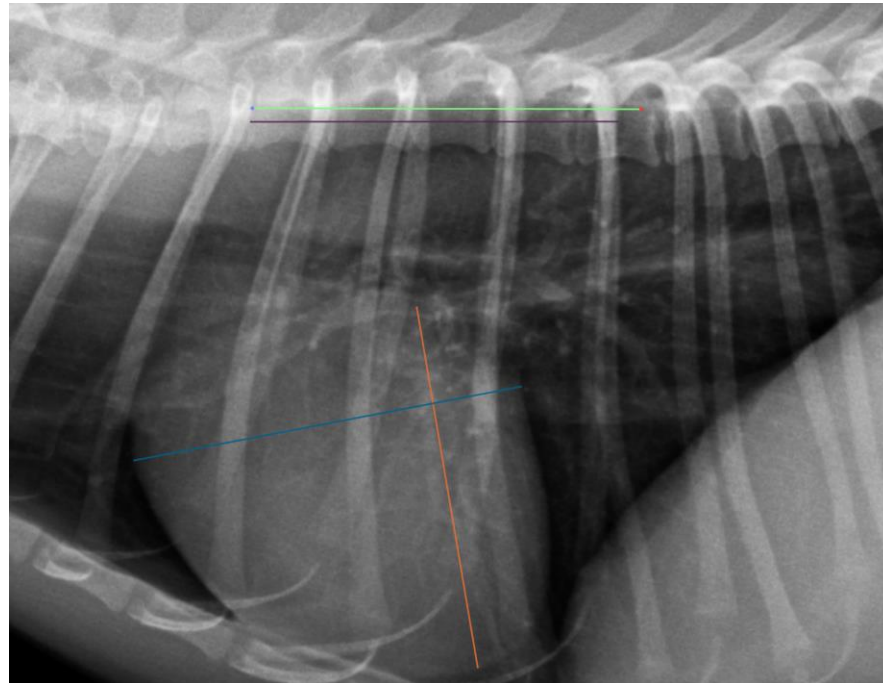
Terrier Yorkshire mix

SEX

Male

AGE

13 Months



INTERPRETED BY

Nele Eley, DVM
Dr. med. Vet. DipECVDI

The information and recommendations provided are based on the images presented by the referring veterinarian/sonographer. No evaluation can be communicated regarding pathology that was not visible in the image/video clips provided.

HOSPITAL NAME

St. Catherine's Animal
Hospital

Thank you for this referral. If the clinical or image interpretation does not parallel your findings or if I can be of any further assistance please contact me.

Nele Eley, DVM, Dr. med. vet., DipECVDI
European Specialist in Veterinary Diagnostic Imaging, Cert. Radiology,
Senior lecturer University of Giessen, Germany, Veterinary Faculty, Department of Radiology
Nele.Eley@sonopath.com

REFERRING VET

Dr. Boctor

INVOICE

55391

DATE

11-26-22