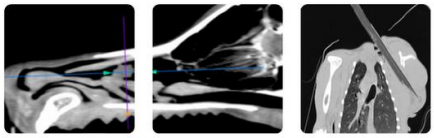

PATIENT
Heidi Hawkins

SPECIES
Canine

BREED
Brittany Spaniel

SEX
FS

AGE
4Y

WEIGHT
18kg

INTERPRETED BY
Nele Eley (Ondreka), DVM Dr. med. vet., DipECVDI

IMAGING PERFORMED BY
David Lane

HOSPITAL NAME
Points East West Veterinary Services

REFERRING VET
David Lane

INVOICE
72759

DATE
11-25-25

PRESENTING CLINICAL SIGNS

Active dog with a chronic intermittent LFL stance phase lameness that is provoked by exercise. Treatment elsewhere with laser and ESWT has not resolved the issue. Both elbows have palpable exostosis and pain on medial coronoid process palpation. The left shoulder demonstrates pain on extension. Under sedation, both shoulders are stable.

ULTRASONOGRAPHIC FINDINGS

Left Shoulder

Mild synovial swelling and anechoic effusion are noted in the left bicipital tendon sheath. The biceps tendon is smoothly delineated and presents no changes of its echoarchitecture or echogenicity. There is no evidence of bicipital groove exostosis.

Maximum average thickness of the left supraspinatus tendon is 7mm. Mild internal remodeling of the tendon tissue is seen. The tendon is, however, smoothly delineated and there is no evidence of biceps impingement.

The infraspinatus muscle condenses and narrows down to a long tendon of even width, smooth outline and regular echogenic fibular echoarchitecture and up to the attachment to the bone surface of the humerus. There is no evidence of enlargement of the infraspinatus bursa.

The subscapularis tendon, teres minor, and visible joint margins present within normal limits.

Right Shoulder

The biceps tendon can be seen from its origin through the bicipital groove, up to the musculotendinous transition and is within normal limits for shape, echogenicity and echoarchitecture. There is no evidence of synovial thickening and no evidence of abnormal effusion. The bone surface of the bicipital groove is even and smooth.

Maximum average thickness of the right supraspinatus tendon is 7mm. Mild internal remodeling of the tendon tissue is seen. The tendon is, however, smoothly delineated and there is no evidence of biceps impingement.

The infraspinatus muscle condenses and narrows down to a long tendon of even width, smooth outline and regular echogenic fibular echoarchitecture and up to the attachment to the bone surface of the humerus. There is no evidence of enlargement of the infraspinatus bursa.

The subscapularis tendon, teres minor, and visible joint margins present within normal limits.

ULTRASONOGRAPHIC DIAGNOSIS

- Mild left shoulder biceps tenosynovitis, otherwise normal ultrasonographic presentation of the rotator cuff and medial compartment of the left shoulder.
- Normal age related ultrasonographic presentation of the right shoulder including biceps tendon, rotator cuff, and medial joint compartment.

INTERPRETATION OF FINDINGS & FURTHER RECOMMENDATIONS

The ultrasonographic study of the left shoulder reveals signs of mild biceps tenosynovitis which can be a consequence of chronic overuse or low grade repetitive micro trauma. The right shoulder is normal supporting the notion that the left limb may be preferentially loaded. Chronic tenosynovitis can

PATIENT
Heidi Hawkins

SPECIES
Canine

BREED
Brittany Spaniel

SEX
FS

AGE
4Y

WEIGHT
18kg

INTERPRETED BY
Nele Eley (Ondreka), DVM Dr. med. vet., DipECVDI

IMAGING PERFORMED BY
David Lane

HOSPITAL NAME
Points East West Veterinary Services

REFERRING VET
David Lane

INVOICE
72759

DATE
11-25-25

contribute to the intermittent lameness and discomfort of the patient, however, coexistence of elbow arthropathy should be born in mind. Controlled exercise, physical therapy, and systemic NSAID treatment should help control the mild biceps tenosynovitis of the left shoulder.

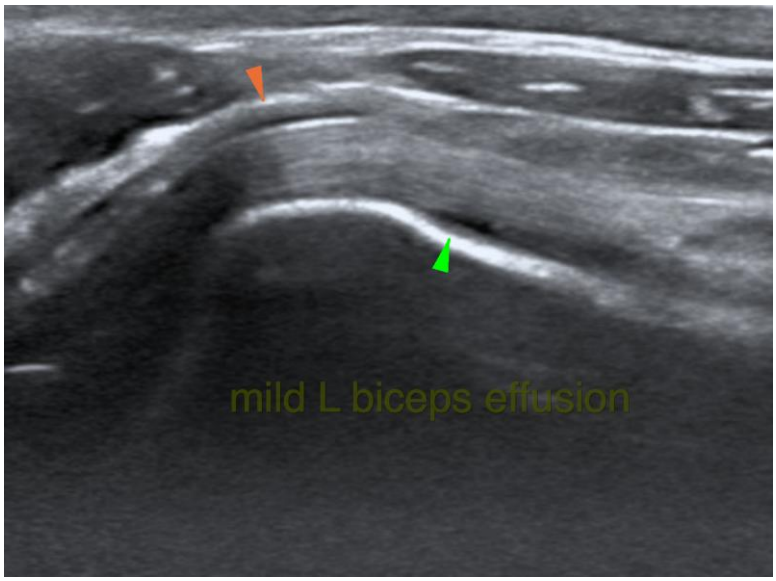

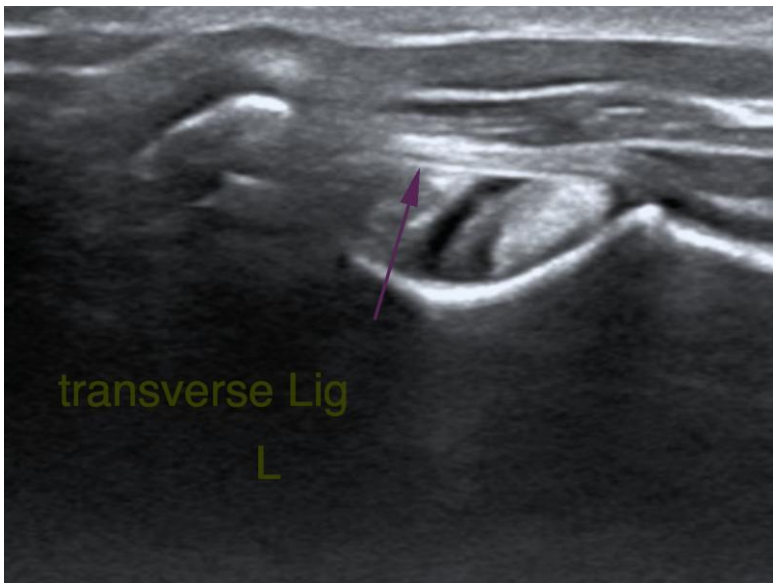

SonoPath
FOSTERING THE ART OF VETERINARY MEDICINE™

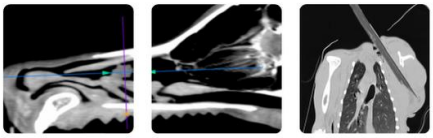

Teleradiology
Educational Teleconsultation Services™

SonoPath.com info@sonopath.com 1.800.838.4268

PATIENT

Heidi Hawkins

SPECIES

Canine

BREED

Brittany Spaniel

SEX

FS

AGE

4Y

WEIGHT

18kg

INTERPRETED BY

Nele Eley (Ondreka), DVM Dr. med. vet., DipECVDI

IMAGING PERFORMED BY

David Lane

HOSPITAL NAME

Points East West Veterinary Services

REFERRING VET

David Lane

INVOICE

72759

DATE

11-25-25

The information and recommendations provided are based on the images presented by the referring veterinarian. No evaluation can be communicated regarding pathology that was not visible in the image/video clips provided.

Thank you for this referral. If the clinical or image interpretation does not parallel your findings or if I can be of any further assistance please contact me.

Nele Eley (Ondreka), DVM, Dr. med. vet., DipECVDI
European Specialist in Veterinary Diagnostic Imaging, Cert. Radiology,
Senior lecturer University of Giessen/Germany, Veterinary Faculty, Department of Radiology.
info@sonopath.com