



PATIENT

Scottie Anne Best

SPECIES

Canine

BREED

Cocker Mix

SEX

FS

AGE

13Y

WEIGHT

23lbs

INTERPRETED BY

Nele Eley (Ondreka),
DVM Dr. med. vet.,
DipECVDI

IMAGING PERFORMED BY

Jose Lopez

HOSPITAL NAME

Westchester Animal
Hospital

REFERRING VET

Randy Dominguez

INVOICE

72715

DATE

11-24-25

PRESENTING CLINICAL SIGNS

Presented with a history of bilateral chronic ear infection. Tumor in right pinnae, TECA will be performed today after the CT scan right ear

COMPUTED TOMOGRAPHIC STUDY OF THE HEAD

Plain and post contrast studies are available for review.

COMPUTED TOMOGRAPHIC FINDINGS

A 13 x 13 x 10mm sized, cauliflower shaped, soft tissue attenuating mass is seen at the base of the right pinna. The mass shows nonuniform contrast enhancement and ill-defined margins.

Moderate thickening of the epithelial lining of the right external auditory meatus is seen. Mild thickening of the epithelial lining of the left external auditory meatus is present. The middle ear presents within normal limits.

The soft palate is long and thick.

The right retropharyngeal lymph node is mildly enlarged with mild nonuniform enhancement.

Evidence of nearly complete tooth extractions with oronasal communication at the removed tooth 204 is seen. Regional destructive rhinitis is noted in the left nasal cavity.

The brain presents no deviation from normal anatomy and symmetry. The grey and white matter distinction and the neuroparenchymal attenuation are as expected. The distribution of contrast enhancement is within normal limits throughout the parenchyma and meninges. The ventricular system is non-dilated and within the limits of the expected volume and symmetry.

COMPUTED TOMOGRAPHIC DIAGNOSIS

- Soft tissue mass at the base of the right pinna meeting neoplastic criteria.
- Mild right retropharyngeal lymphadenomegaly.
- Moderate signs of right sided otitis externa.
- Mild signs of left sided otitis externa.
- No evidence of otitis media or interna.
- Post-extraction changes of the dental arcades with oronasal communication and regional destructive rhinitis level with the removed triadan 204.
- Suspect elongation and thickening of the soft palate.

INTERPRETATION OF FINDINGS & FURTHER RECOMMENDATIONS

The CT findings support the presence of a soft tissue neoplasia at the base of the right pinna. Carcinoma such as squamous cell carcinoma, ceruminous cell carcinoma, sarcoma, adenoma, and other are possible differential diagnoses. Definitive diagnosis will require histopathology. Proceed with planned TECA on the right ear. Follow up by histopathologic examination.

The findings of the right retropharyngeal lymph node are likely reactive. Early metastatic disease cannot be completely excluded but is considered by far less likely. FNA of the right retropharyngeal lymph node can be considered.

The findings of the dental arcade and nasal cavity as well as of the palate require clinical correlation.



PATIENT

Scottie Anne Best

SPECIES

Canine

BREED

Cocker Mix

SEX

FS

AGE

13Y

WEIGHT

23lbs

INTERPRETED BY

Nele Eley (Ondreka),
DVM Dr. med. vet.,
DipECVDI

IMAGING PERFORMED BY

Jose Lopez

HOSPITAL NAME

Westchester Animal
Hospital

REFERRING VET

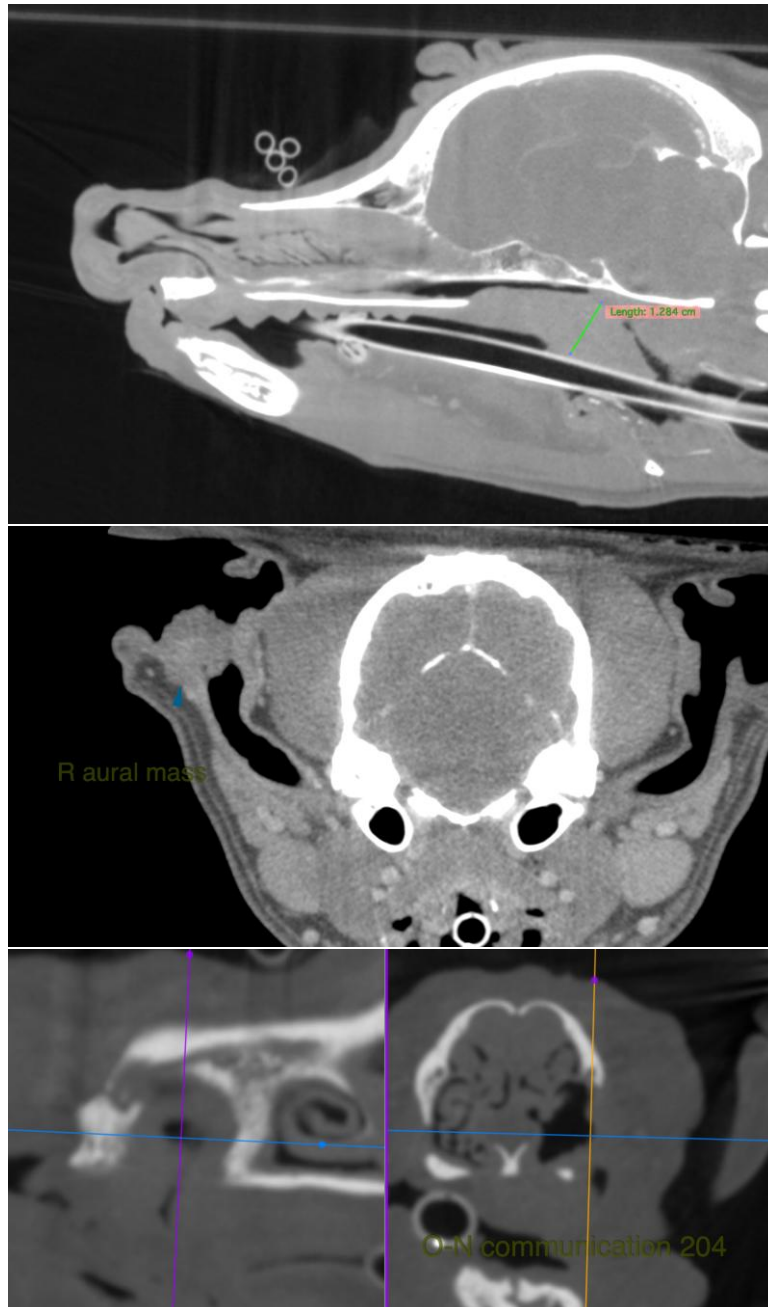
Randy Dominguez

INVOICE

72715

DATE

11-24-25





PATIENT

Scottie Anne Best

SPECIES

Canine

BREED

Cocker Mix

SEX

FS

AGE

13Y

WEIGHT

23lbs

INTERPRETED BY

Nele Eley (Ondreka),
DVM Dr. med. vet.,
DipECVDI

IMAGING PERFORMED BY

Jose Lopez

HOSPITAL NAME

Westchester Animal
Hospital

REFERRING VET

Randy Dominguez

INVOICE

72715

DATE

11-24-25

The information and recommendations provided are based on the images presented by the referring veterinarian. No evaluation can be communicated regarding pathology that was not visible in the image/video clips provided.

Thank you for this referral. If the clinical or image interpretation does not parallel your findings or if I can be of any further assistance please contact me.

Nele Eley (Ondreka), DVM, Dr. med. vet., DipECVDI

European Specialist in Veterinary Diagnostic Imaging, Cert. Radiology,

Senior lecturer University of Giessen/Germany, Veterinary Faculty, Department of Radiology.

info@sonopath.com