

PATIENT

Ginny Mencil

SPECIES

Canine

BREED

Beagle

SEX

F

AGE

13W

WEIGHT

11.2

INTERPRETED BY

Nele Eley (Ondreka),
DVM Dr. med. vet.,
DipECVDI

IMAGING PERFORMED BY

Mallory

HOSPITAL NAME

The Pet Hospital of
Stratford

REFERRING VET

Dr. Giuliani

INVOICE

72714

DATE

11-24-25

PRESENTING CLINICAL SIGNS

recheck of rads from 11/12 for pneumonia. P still currently on abx. Doing well per o.

RADIOGRAPHIC STUDY OF THE THORAX

Right/left lateral and ventrodorsal views of the thorax totaling 3 images available for review.

RADIOGRAPHIC FINDINGS

Compared to prior report dated 11-10-25.

The pulmonary inflation is deep.

The previously described cranioventral patchy alveolar infiltrate is almost completely resolved.

A mild diffuse bronchointerstitial pattern persists.

The cardiac silhouette is within normal limits. The VHS is 10, which is stable and normal for age.

The trachea is normal in position and diameter.

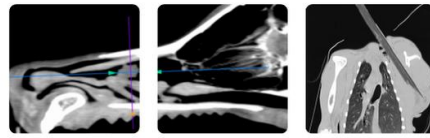
A normal thymic remnant is seen in the cranioventral mediastinum.

RADIOGRAPHIC DIAGNOSIS

- Near complete resolution of prior cranioventral alveolar infiltrate.
- Mild residual diffuse bronchointerstitial pattern consistent with resolving airway inflammation.
- Normal cardiac silhouette and trachea.

INTERPRETATION OF FINDINGS & FURTHER RECOMMENDATIONS

Compared with the prior study from 11-10, the radiographic findings indicate significant improvement of bronchopneumonia with near complete clearing of the alveolar consolidation. A mild diffuse bronchointerstitial pattern persists which is compatible with resolving infectious airway disease. Completion of the current course of antibiotics and ongoing clinical monitoring are recommended.



PATIENT

Ginny Mencil

SPECIES

Canine

BREED

Beagle

SEX

F

AGE

13W

WEIGHT

11.2

INTERPRETED BY

Nele Eley (Ondreka),
DVM Dr. med. vet.,
DipECVDI

IMAGING PERFORMED BY

Mallory

HOSPITAL NAME

The Pet Hospital of
Stratford

REFERRING VET

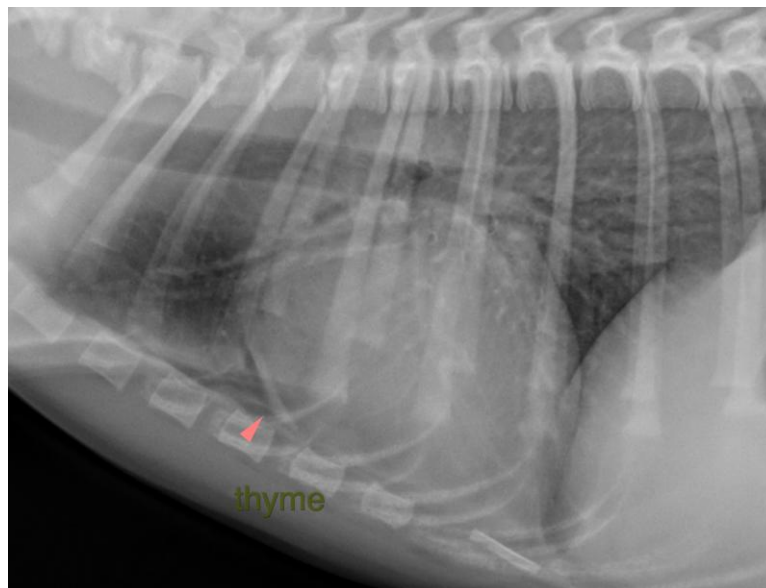
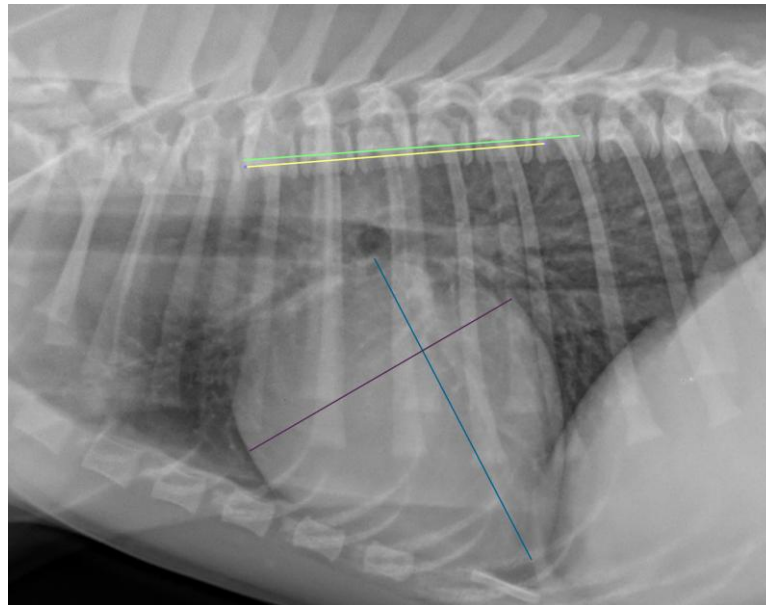
Dr. Giuliani

INVOICE

72714

DATE

11-24-25



The information and recommendations provided are based on the images presented by the referring veterinarian. No evaluation can be communicated regarding pathology that was not visible in the image/video clips provided.

Thank you for this referral. If the clinical or image interpretation does not parallel your findings or if I can be of any further assistance please contact me.

Nele Eley (Ondreka), DVM, Dr. med. vet., DipECVDI
European Specialist in Veterinary Diagnostic Imaging, Cert. Radiology,
Senior lecturer University of Giessen/Germany, Veterinary Faculty, Department of Radiology.
info@sonopath.com