

**PATIENT**

Freddy Smith

PRESENTING CLINICAL SIGNS

For about a week now he has been having a real raspy and wheezy cough and it mainly happens at night when he is relaxing. Has been seeing some snot/ water come out of his nose as well.
Abnormal PE/Chem/CBC/UA Results: PE: Tachypnea 190 Tachycardia 200 Everything look good other wise. NO RECENT LABS

SPECIES

Feline

RADIOGRAPHIC STUDY OF THE THORAX

Right/left lateral and ventrodorsal views of the thorax totaling 3 images available for review.

BREED

Siamese Mix

RADIOGRAPHIC FINDINGS

The degree of pulmonary inflation is moderate. A moderate generalized bronchial lung pattern with mild peribronchial cuffing and caudodorsal accentuation is seen.

SEX

Neutered

There is no evidence of cardiovascular pathology. The cardiac silhouette presents within normal limits and with no evidence of generalized enlargement or specific chamber enlargement. The pulmonary vasculature presents within normal limits.

AGE

15 Years

Course and width of the trachea are considered within normal limits.

There is no evidence of abnormal mediastinal widening.

Mild mid thoracic spondyloses are seen.

INTERPRETED BY

Nele Eley, DVM
Dr. med. Vet. DipECVDI

RADIOGRAPHIC DIAGNOSIS

- Moderate generalized bronchial lung pattern with mild peribronchial cuffing.

HOSPITAL NAME

Elizabeth Animal
Hospital

INTERPRETATION OF THE FINDINGS & FURTHER RECOMMENDATIONS

The radiographic findings are compatible with chronic lower airway disease. Feline allergic lower airway syndrome is considered a likely explanation of the radiographic findings and clinical signs. Infectious bronchitis such as viral, bacterial, parasitic, or protozoal is a potential differential diagnosis. A clinical trial of treatment for feline asthma could be considered versus lower airway sampling for further definition.

REFERRING VET

Leon Anderson, DVM

INVOICE

55313

DATE

11-21-22



PATIENT

Freddy Smith

SPECIES

Feline

BREED

Siamese Mix

SEX

Neutered

AGE

15 Years

INTERPRETED BY

Nele Eley, DVM
Dr. med. Vet. DipECVDI

HOSPITAL NAME

Elizabeth Animal
Hospital

REFERRING VET

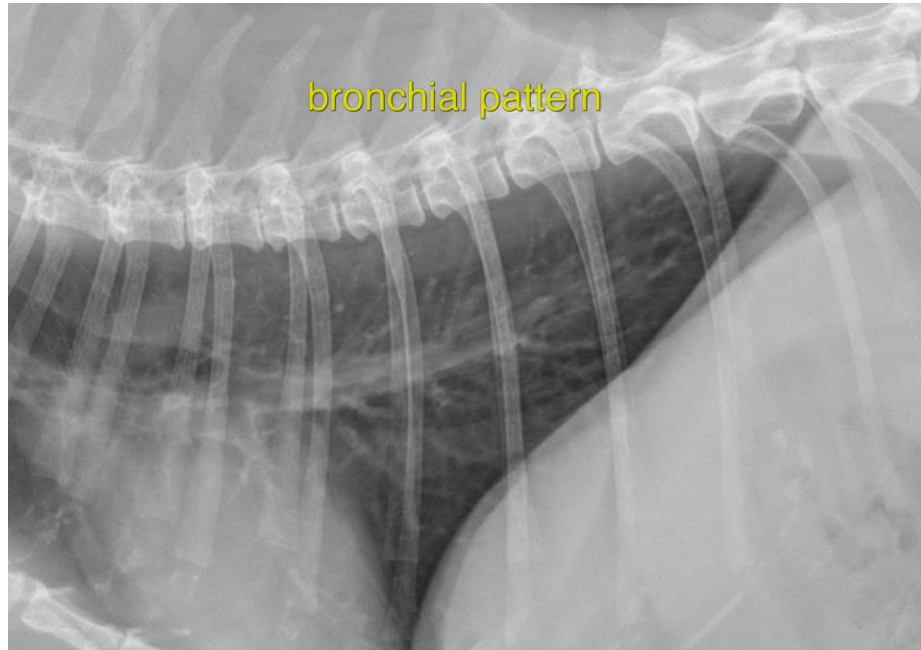
Leon Anderson, DVM

INVOICE

55313

DATE

11-21-22



The information and recommendations provided are based on the images presented by the referring veterinarian/sonographer. No evaluation can be communicated regarding pathology that was not visible in the image/video clips provided.

Thank you for this referral. If the clinical or image interpretation does not parallel your findings or if I can be of any further assistance please contact me.

Nele Eley, DVM, Dr. med. vet., DipECVDI
European Specialist in Veterinary Diagnostic Imaging, Cert. Radiology,
Senior lecturer University of Giessen, Germany, Veterinary Faculty, Department of Radiology
Nele.Eley@sonopath.com