

**PATIENT**

Bunni Cadeddu

PRESENTING CLINICAL SIGNS

of choking /hacking with weird noise, had full mouth extractions
Abnormal PE/Chem/CBC/UA Results: no abnormal lung sounds was noticed during exam.

SPECIES

Canine

RADIOGRAPHIC STUDY OF THE THORAX

Right/left lateral and ventrodorsal views totaling 3 images available for review.

BREED

Yorkshire Terrier

RADIOGRAPHIC FINDINGS

The radiographic presentation of the cardiac silhouette is within normal limits. The vertebral heart score is 9.5. No evidence of pulmonary vascular congestion is seen.

Redundancy of the dorsal tracheal ligament of the cervical trachea is seen as well as mild cervical tracheal collapse.

SEX

Male

The lung and bronchial tree present within age related normal limits.

There is no evidence of mediastinal widening.

AGE

10 Years

There is moderate gastric aerophagia in a post-prandial stomach.

INTERPRETED BY

Nele Eley, DVM
Dr. med. Vet. DipECVDI

- Redundancy of the tracheal membrane with mild tracheal collapse.
- Radiographically normal heart, lung, and bronchial tree.
- Aerophagia.

INTERPRETATION OF THE FINDINGS & FURTHER RECOMMENDATIONS

HOSPITAL NAME
St. Catherine's Animal
Hospital

Collapsing trachea is considered a significant potential in this patient even though the trachea is mostly patent during the radiographic exposure. The redundancy of the dorsal tracheal membrane may be associated with dynamic tracheal collapse especially with the pertinent history and patient demographics. No other explanation for the clinical signs is seen in the lung, bronchial tree, or heart. Other upper respiratory tract involvement should be ruled out.

REFERRING VET

Dr. Masoud

The aerophagia is thought to be due to respiratory distress or general excitement.

INVOICE

48181

DATE

11-2-21



PATIENT

Bunni Cadeddu

SPECIES

Canine

BREED

Yorkshire Terrier

SEX

Male

AGE

10 Years

INTERPRETED BY

Nele Eley, DVM
Dr. med. Vet. DipECVDI

HOSPITAL NAME

St. Catherine's Animal
Hospital

REFERRING VET

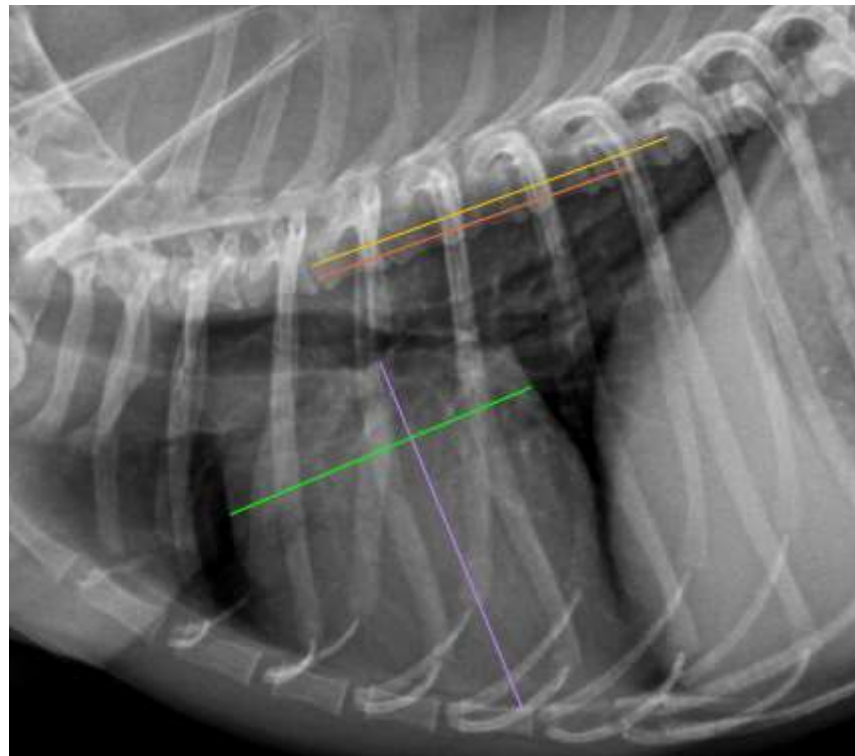
Dr. Masoud

INVOICE

48181

DATE

11-2-21



The information and recommendations provided are based on the images presented by the referring veterinarian. No evaluation can be communicated regarding pathology that was not visible in the image/video clips provided.

Thank you for this referral. If the clinical or image interpretation does not parallel your findings or if I can be of any further assistance please contact me.

Nele Eley, DVM, Dr. med. vet., DipECVDI
European Specialist in Veterinary Diagnostic Imaging, Cert. Radiology,
Senior lecturer University of Giessen, Germany, Veterinary Faculty, Department of Radiology
Nele.Eley@sonopath.com