



PATIENT

Zoe Cornett

PRESENTING CLINICAL SIGNS

Lethargic
Abnormal PE/Chem/CBC/UA Results: Fructosamine 365.4 umol, glucose uria

SPECIES

Feline

RADIOGRAPHIC STUDY OF THE ABDOMEN

Right/left lateral and ventrodorsal views of the abdomen totaling 3 images available for review.

BREED

Domestic Shorthair

RADIOGRAPHIC FINDINGS

The patient is obese.

The abdominal serosal detail appears to be maintained.

SEX

Female Spayed

The left kidney is reduced in size. The right kidney presents within normal limits.

Gastrointestinal aerophagia is seen with no evidence of abnormal dilation of the intestine.

A small amount of fecal matter is present within the colon.

AGE

9 Years

The urinary bladder is moderately distended and presents within normal limits.

The liver and spleen present within normal limits as well.

INTERPRETED BY

Nele Eley, DVM
Dr. med. Vet. DipECVDI

RADIOGRAPHIC DIAGNOSIS

- Nephropathy with reduced size of the left kidney.
- Gastrointestinal maldigestion pattern.

HOSPITAL NAME

St. Catherine's Animal
Hospital

INTERPRETATION OF THE FINDINGS & FURTHER RECOMMENDATIONS

Differential diagnosis for the reduced size of the left kidney includes congenital abnormality such as hypoplasia as well as chronic nephritis. To correlate with the laboratory values, renal staging could be considered.

REFERRING VET

Dr. Jui Gokhale

An unspecific gastrointestinal maldigestion pattern suggesting potential for functional ileus is seen. There is no evidence of mechanical ileus.

INVOICE

55279

DATE

11-18-22



PATIENT

Zoe Cornett

SPECIES

Feline

BREED

Domestic Shorthair

SEX

Female Spayed

AGE

9 Years

INTERPRETED BY

Nele Eley, DVM
Dr. med. Vet. DipECVDI

HOSPITAL NAME

St. Catherine's Animal
Hospital

REFERRING VET

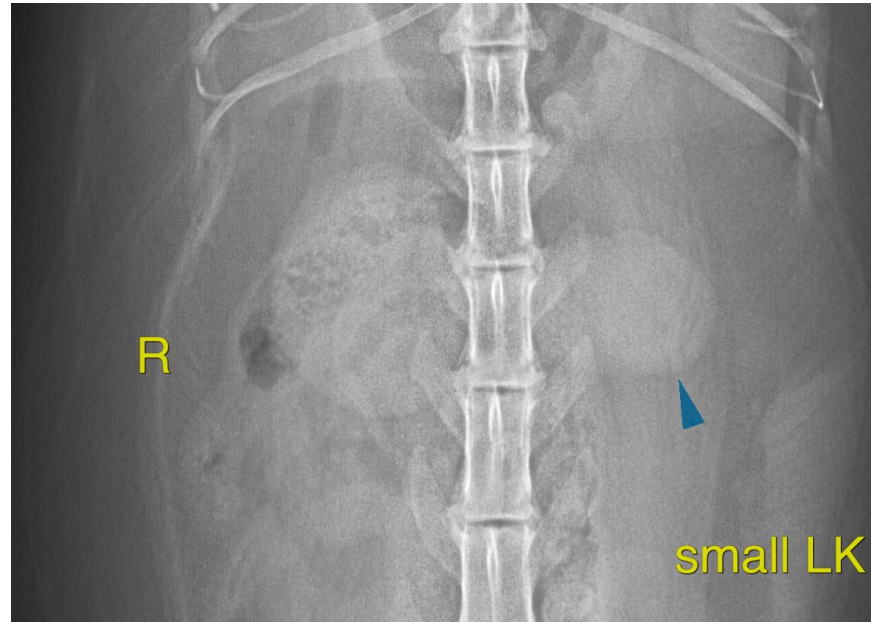
Dr. Jui Gokhale

INVOICE

55279

DATE

11-18-22



The information and recommendations provided are based on the images presented by the referring veterinarian/sonographer. No evaluation can be communicated regarding pathology that was not visible in the image/video clips provided.

Thank you for this referral. If the clinical or image interpretation does not parallel your findings or if I can be of any further assistance please contact me.

Nele Eley, DVM, Dr. med. vet., DipECVDI
European Specialist in Veterinary Diagnostic Imaging, Cert. Radiology,
Senior lecturer University of Giessen, Germany, Veterinary Faculty, Department of Radiology
Nele.Eley@sonopath.com