



PATIENT

Sheila Rose 25-312
DVGRR

SPECIES

Canine

BREED

Mini Golden Doodle

SEX

Female

AGE

6Y

WEIGHT

20lbs

INTERPRETED BY

Nele Eley (Ondreka),
DVM Dr. med. vet.,
DipECVDI

IMAGING PERFORMED BY

Dr. Amicone

HOSPITAL NAME

New Holland
Veterinary Hospital

REFERRING VET

Dr. Amicone

INVOICE

72642

DATE

11-17-25

PRESENTING CLINICAL SIGNS

Arrived at rescue and on exam had 2/6 heart murmur - no signs of heart disease, acting normal. 3 view thoracic rads done to evaluate for anesthesia.

Abnormal PE/Chem/CBC/UA Results: Lyme +, CBC/Chem: mild monocytosis PE: 2/6 HM, left apical holosystolic

RADIOGRAPHIC STUDY OF THE THORAX

Right/left lateral and ventrodorsal views of the thorax totaling 3 images available for review in jpg format.

RADIOGRAPHIC FINDINGS

The cardiac silhouette is within normal limits. No radiographic evidence of structural remodeling of the cardiac silhouette is seen. There is no evidence of overall cardiomegaly or specific chamber enlargement. The VHS is 9.4, which is within the reference range. The pulmonary vasculature is normal in size and distribution.

The lungs present normal aeration. No evidence of consolidation, masses, interstitial bronchial, or alveolar patterns is seen.

There is no evidence of pleural effusion.

The mediastinum is unremarkable.

RADIOGRAPHIC DIAGNOSIS

- Radiographically normal thorax.
- No evidence of structural heart disease or pulmonary pathology.

INTERPRETATION OF FINDINGS & FURTHER RECOMMENDATIONS

There are no radiographic signs of cardiomegaly, cardiac remodeling, or congestive heart failure. The clinically detected heart murmur is not associated with any detectable structural cardiac changes. The lungs and pulmonary vasculature appear normal and there are no signs of heart failure. The currently negative radiographic findings may indicate a physiologic/innocent heart murmur. Routine monitoring of heart murmur is recommended as clinically indicated. Radiographic contraindications to anesthesia are not noted. Consider echocardiography if murmur changes, clinical signs develop, or for baseline evaluation.



PATIENT

Sheila Rose 25-312
DVGRR

SPECIES

Canine

BREED

Mini Golden Doodle

SEX

Female

AGE

6Y

WEIGHT

20lbs

INTERPRETED BY

Nele Eley (Ondreka),
DVM Dr. med. vet.,
DipECVDI

IMAGING PERFORMED BY

Dr. Amicone

HOSPITAL NAME

New Holland
Veterinary Hospital

REFERRING VET

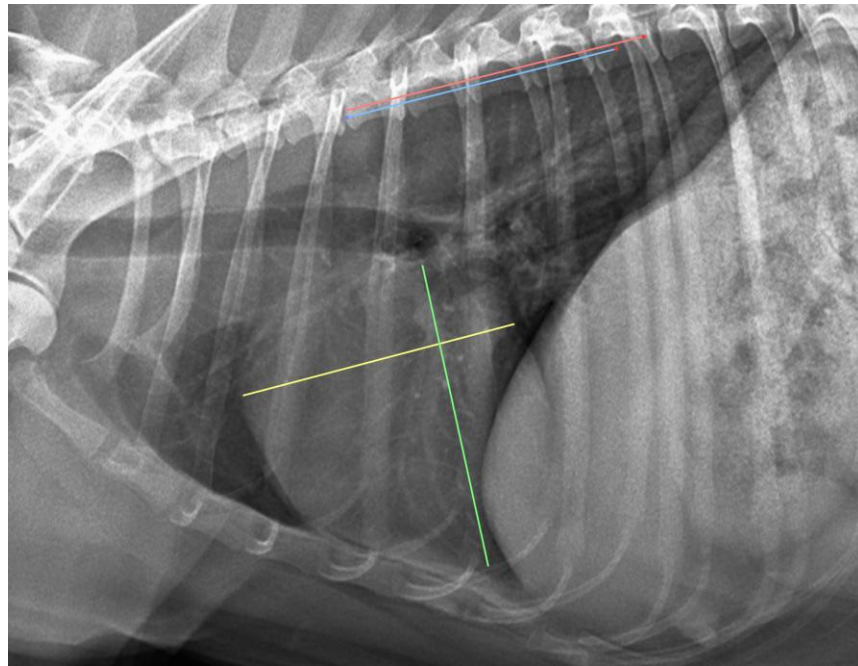
Dr. Amicone

INVOICE

72642

DATE

11-17-25



The information and recommendations provided are based on the images presented by the referring veterinarian. No evaluation can be communicated regarding pathology that was not visible in the image/video clips provided.

Thank you for this referral. If the clinical or image interpretation does not parallel your findings or if I can be of any further assistance please contact me.

Nele Eley (Ondreka), DVM, Dr. med. vet., DipECVDI

European Specialist in Veterinary Diagnostic Imaging, Cert. Radiology,
Senior lecturer University of Giessen/Germany, Veterinary Faculty, Department of Radiology.
info@sonopath.com