



PATIENT

River Drury

SPECIES

Canine

BREED

Munsterlander

SEX

MN

AGE

8Y

WEIGHT

26kg

INTERPRETED BY

Nele Eley (Ondreka),
DVM Dr. med. vet.,
DipECVDI

IMAGING PERFORMED BY

David Lane

HOSPITAL NAME

Points East West
Veterinary Services

REFERRING VET

David Lane

INVOICE

72662

DATE

11-17-25

PRESENTING CLINICAL SIGNS

Chronic history of wax/wane RFL 3/5 lameness induced by exercise. Examination revealed pain on palpation of the right glenohumeral medial compartment, and mildly on abduction. Abduction angle is greater (30 degrees) on the right compared to the left (20 degrees) with a softer end feel.

ULTRASONOGRAPHIC FINDINGS

Left Shoulder

Mild biceps tendon sheath thickening and anechoic effusion is noted. The biceps tendon shape and structure appear preserved with no evidence of alterations of the fiber pattern and no evidence of structural compromise.

Mild biceps tendon impingement is present secondary to supraspinatus tendinopathy. Moderate remodeling of the supraspinatus tendon with early enthesiophyte formation and multiple small echogenic foci are seen. Maximum average thickness of the left supraspinatus tendon is 8mm.

The left subscapularis and medial glenohumeral ligament appear normal.

Right Shoulder

Mild biceps tendon sheath thickening and anechoic effusion is noted. The biceps tendon shape and structure appear preserved with no evidence of alterations of the fiber pattern and no evidence of structural compromise.

Mild biceps tendon impingement is present secondary to supraspinatus tendinopathy. Moderate remodeling of the supraspinatus tendon with early enthesiophyte formation and multiple small echogenic foci are seen. Maximum average thickness of the right supraspinatus tendon is 8mm.

The subscapularis tendon is mildly thickened with a thin hypoechoic halo. The right medial glenohumeral ligament shows thickening of more than 2mm with distal accentuation.

ULTRASONOGRAPHIC DIAGNOSIS

- Mild bilateral biceps tenosynovitis with preserved tendon structure.
- Moderate bilateral supraspinatus tendinopathy.
- Mild right subscapularis tendon thickening and desmopathy of the right medial glenohumeral ligament with distal accentuation.

INTERPRETATION OF FINDINGS & FURTHER RECOMMENDATIONS

The ultrasound demonstrates mild degenerative and inflammatory changes in both shoulders with more pronounced alterations in the medial compartment of the right shoulder correlating with the patient's exercise induced lameness and increased abduction angle. The medial compartment of the left shoulder remains largely normal.

Significance of the mild biceps tenosynovitis is uncertain. Mild biceps impingement secondary to supraspinatus remodeling is noted bilaterally. However, the changes are subtle at this point.

Consider targeted conservative management for the right shoulder, including anti-inflammatory therapy, pain management, physiotherapy, and controlled exercise. Intraarticular regenerative therapy (PRP) could be considered as well.



PATIENT

River Drury

SPECIES

Canine

BREED

Munsterlander

SEX

MN

AGE

8Y

WEIGHT

26kg

INTERPRETED BY

Nele Eley (Ondreka),
DVM Dr. med. vet.,
DipECVDI

IMAGING PERFORMED BY

David Lane

HOSPITAL NAME

Points East West
Veterinary Services

REFERRING VET

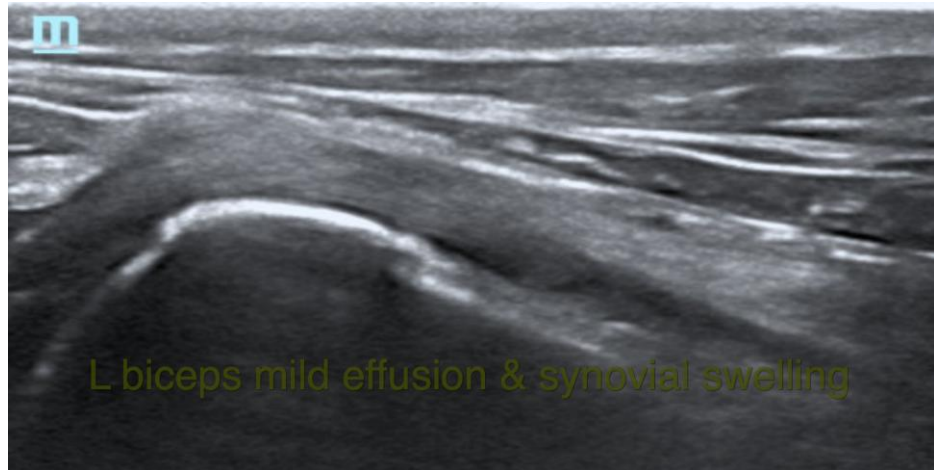
David Lane

INVOICE

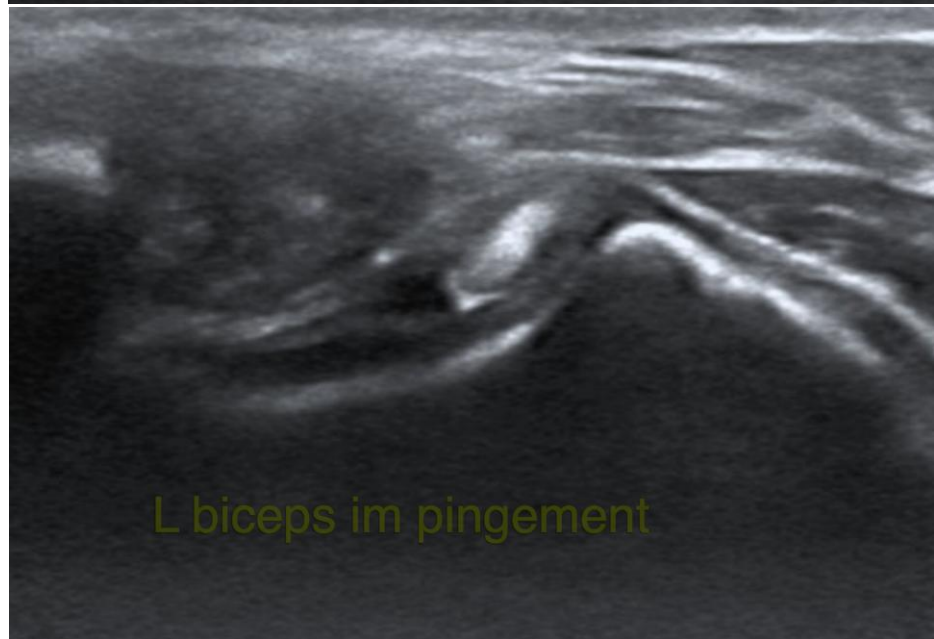
72662

DATE

11-17-25



L biceps mild effusion & synovial swelling



L biceps im pingement



PATIENT

River Drury

SPECIES

Canine

BREED

Munsterlander

SEX

MN

AGE

8Y

WEIGHT

26kg

INTERPRETED BY

Nele Eley (Ondreka),
DVM Dr. med. vet.,
DipECVDI

IMAGING PERFORMED BY

David Lane

HOSPITAL NAME

Points East West
Veterinary Services

REFERRING VET

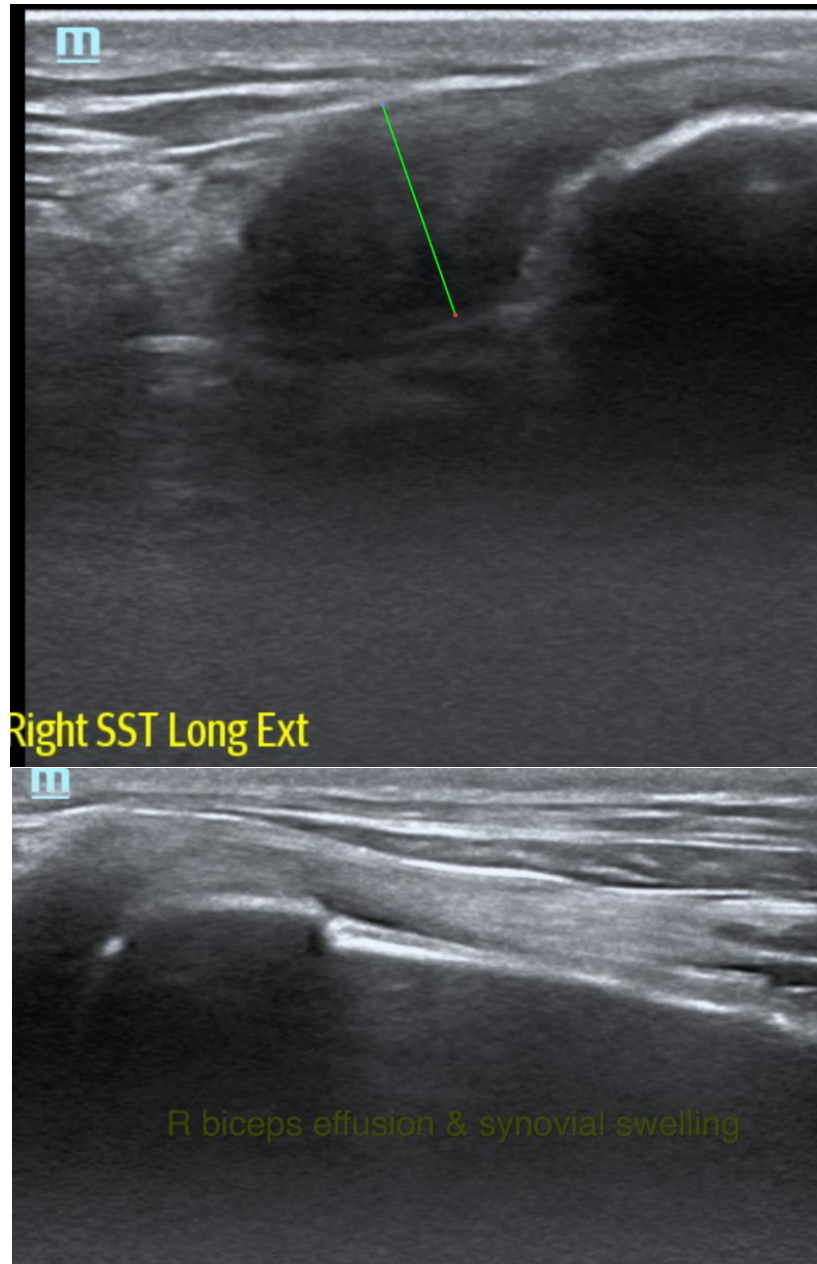David Lane

INVOICE

72662

DATE

11-17-25





PATIENT

River Drury

SPECIES

Canine

BREED

Munsterlander

SEX

MN

AGE

8Y

WEIGHT

26kg

INTERPRETED BY

Nele Eley (Ondreka),
DVM Dr. med. vet.,
DipECVDI

IMAGING PERFORMED BY

David Lane

HOSPITAL NAME

Points East West
Veterinary Services

REFERRING VET

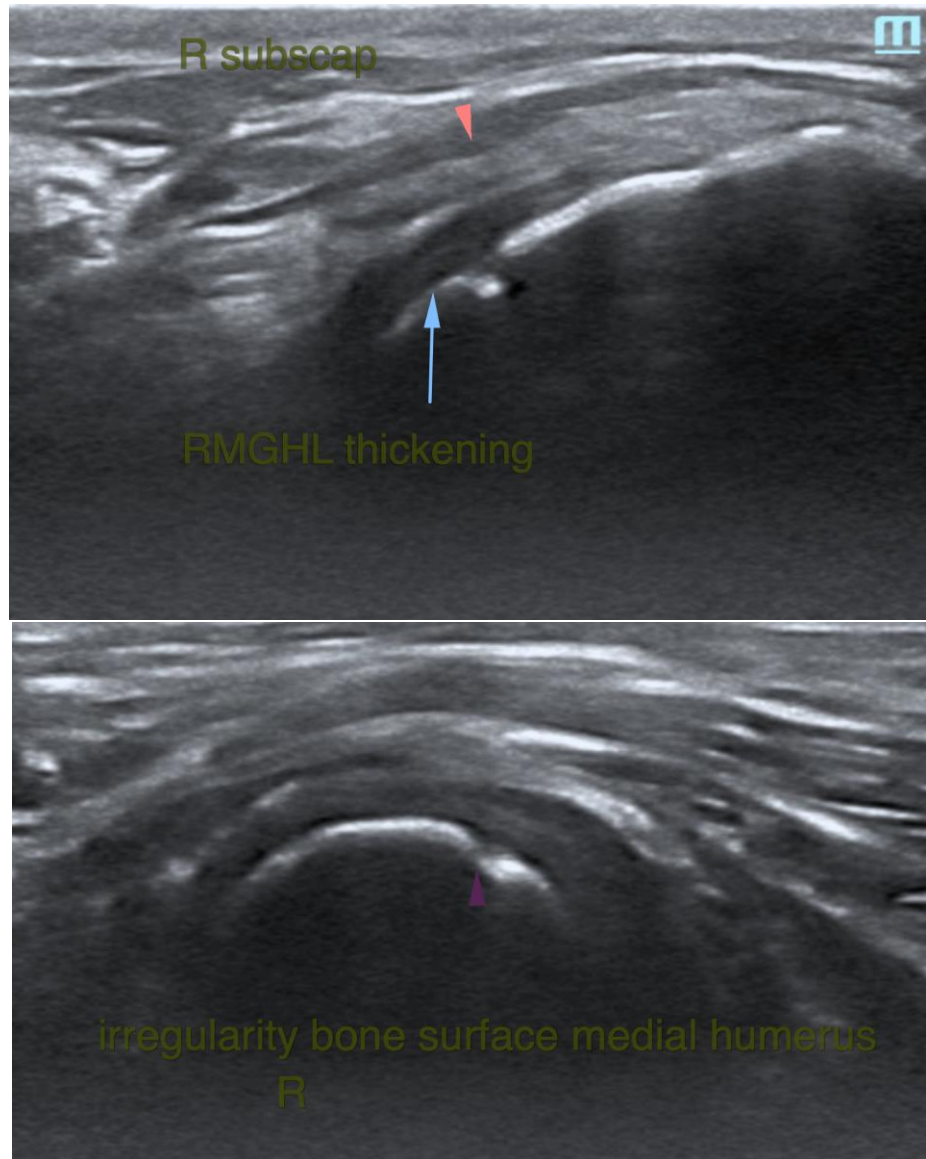
David Lane

INVOICE

72662

DATE

11-17-25



The information and recommendations provided are based on the images presented by the referring veterinarian. No evaluation can be communicated regarding pathology that was not visible in the image/video clips provided.

Thank you for this referral. If the clinical or image interpretation does not parallel your findings or if I can be of any further assistance please contact me.

Nele Eley (Ondreka), DVM, Dr. med. vet., DipECVDI
European Specialist in Veterinary Diagnostic Imaging, Cert. Radiology,
Senior lecturer University of Giessen/Germany, Veterinary Faculty, Department of Radiology.
info@sonopath.com