

**PATIENT**

Ruff Ruff Blake

SPECIES

Canine

BREED

Shih Tzu Mix

SEX

FS

AGE

14 Years

INTERPRETED BYNele Eley, DVM
Dr. med. Vet. DipECVDI**HOSPITAL NAME**Boca Park Animal
Hospital**REFERRING VET**

Ashman

INVOICE

48439

DATE

11-17-21

PRESENTING CLINICAL SIGNS

Presented for sudden onset of ADR. O reports yesterday Ruff Ruff seemed off - weak, not herself, and wobbly. She was groomed by an at home groomer. Today she continues to be extremely lethargic, does not want to move or walk much and shows no interest in food. No current medications or past medical conditions.

Abnormal PE/Chem/CBC/UA Results: - PE - T: 103.3, dull mentation, P very painful on palpation of thoraco-lumbar spine; whining, ventroflexion, and muscle fasciculations. Generally tense throughout entire abdomen. P is bearing less weight on the RH limb with delayed CP in RH, absent panniculus reflex. - CBC/Chem/UA/T4 pending

RADIOGRAPHIC STUDY OF THE THORACOLUMBAR SPINE

Lateral and ventrodorsal views totaling 5 images available for review.

RADIOGRAPHIC FINDINGS

Severe intervertebral disc space narrowing, vertebral end plate sclerosis, and spondylosis deformans are seen at T13/L1 and L1/2. Mild kyphosis is noted between T13/L1 and L1/2.

Mineral opacity is superimposed onto the neuroforamen T13/L1.

Mild spondylosis is present between T11/12 and L2/3.

A mineral opacity is superimposed onto the soft tissue between the dorsal spinous processes between T4 and T5.

RADIOGRAPHIC DIAGNOSIS

- Radiographic evidence of chronic intervertebral disc disease between T13/L1 and L1/2.
- Spondyloses T12 through L3.

INTERPRETATION OF THE FINDINGS & FURTHER RECOMMENDATIONS

The radiographic findings suggest presence of mineralized disc hernia between T13 and L1. There are signs of chronicity. Similar findings, however, without presence of mineralized disc material level with the vertebral canal or neuroforamen are seen between L1 and L2. If a more detailed assessment is warranted, cross sectional imaging such as CT or MRI should be considered.



PATIENT

Ruff Ruff Blake

SPECIES

Canine

BREED

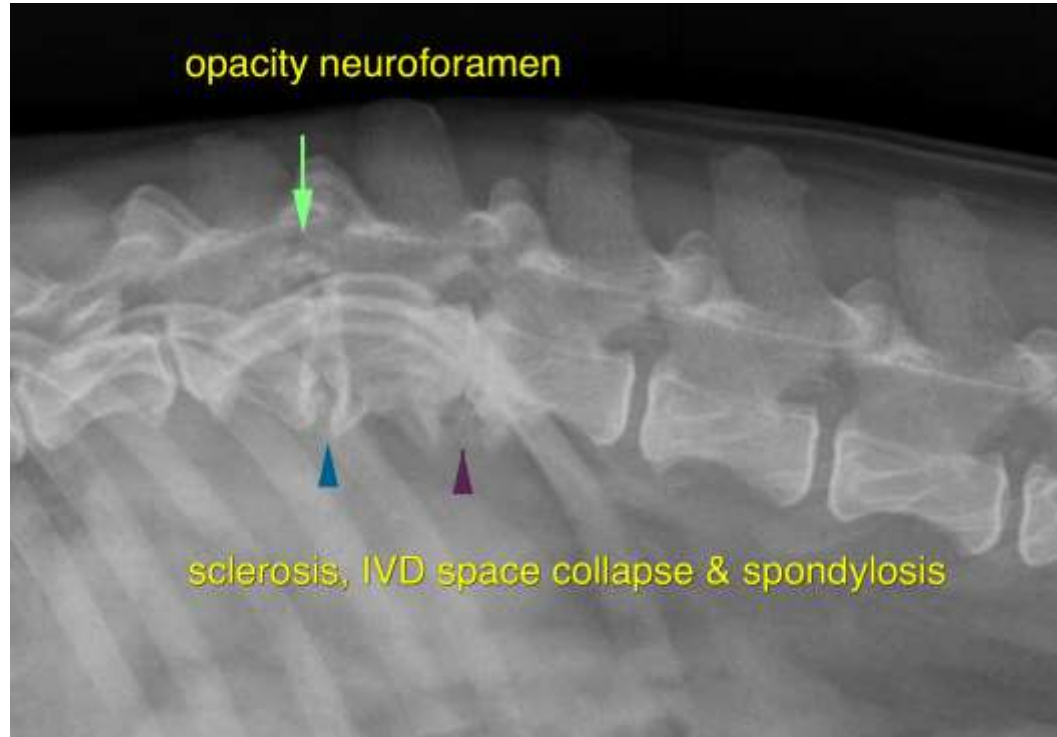
Shih Tzu Mix

SEX

FS

AGE

14 Years



INTERPRETED BY

Nele Eley, DVM
Dr. med. Vet. DipECVDI

The information and recommendations provided are based on the images presented by the referring veterinarian. No evaluation can be communicated regarding pathology that was not visible in the image/video clips provided.

HOSPITAL NAME

Boca Park Animal
Hospital

Thank you for this referral. If the clinical or image interpretation does not parallel your findings or if I can be of any further assistance please contact me.

Nele Eley, DVM, Dr. med. vet., DipECVDI
European Specialist in Veterinary Diagnostic Imaging, Cert. Radiology,
Senior lecturer University of Giessen, Germany, Veterinary Faculty, Department of Radiology
Nele.Eley@sonopath.com

REFERRING VET

Ashman

INVOICE

48439

DATE

11-17-21