

**PATIENT**

Poppy Dove

**SPECIES**

Canine

**BREED**

Mixed

**SEX**

Spayed Female

**AGE**

2 Years

**INTERPRETED BY**Nele Eley, DVM  
Dr. med. Vet. DipECVDI**HOSPITAL NAME**Neel Veterinary  
Hospital**REFERRING VET**

Dr. Deepan Kishore

**INVOICE**

48393

**DATE**

11-16-21

**PRESENTING CLINICAL SIGNS**

Limping on front right leg. Sunday 10/24 went for a walk and limp was pretty bad after about a block away from home. When she gets up she doesn't put much weight on front right leg. Has progressively gotten worse throughout the past week. Last 2 weeks has been on Cosequin 2 a day. Patient has also been given Adequan injections with RDVM. Unable to elicit a pain response in clinic. Patient also has not limped when in clinic.

Abnormal PE/Chem/CBC/UA Results: WNL, Canine 4DX panel negative

**COMPUTED TOMOGRAPHIC STUDY OF THE ELBOWS & SHOULDERS**

Plain and post contrast studies available for review.

There are still issues with count stealing and streak artifacts emanating from the gas/fluid interfaces in the positioning aides, but we will reach out to you soon for further clarification.

**COMPUTED TOMOGRAPHIC FINDINGS**

Based on the available study, there is no evidence of fragmentation or fissuring in either of the medial coronoid processes. The subchondral bone surfaces present intact and smooth. No evidence of periarticular osteophytes is seen and there is no evidence of joint space incongruity.

Both shoulder joints present within normal limits. There is no evidence of osteochondritis or osteoarthritic changes.

**COMPUTED TOMOGRAPHIC DIAGNOSIS**

- Structurally normal CT study of the front limbs.

**INTERPRETATION OF THE FINDINGS & FURTHER RECOMMENDATIONS**

The additional scan does not reveal evidence of elbow dysplasia or other structural pathology in the elbows or shoulders. Next to soft tissue trauma or inflammation, neurologic disease appears to be a potential consideration in this patient.



**PATIENT**

Poppy Dove

**SPECIES**

Canine

**BREED**

Mixed

**SEX**

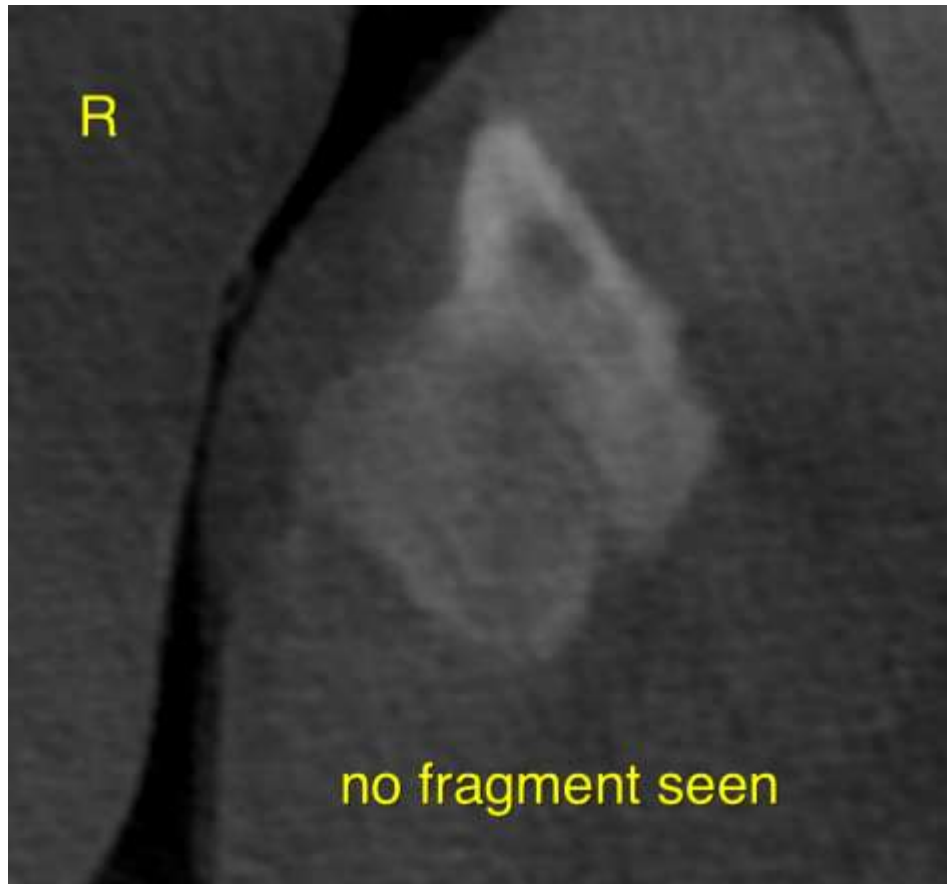
Spayed Female

**AGE**

2 Years

**INTERPRETED BY**

Nele Eley, DVM  
Dr. med. Vet. DipECVDI



**HOSPITAL NAME**

Neel Veterinary  
Hospital

**REFERRING VET**

Dr. Deepan Kishore

**INVOICE**

48393

**DATE**

11-16-21

The information and recommendations provided are based on the images presented by the referring veterinarian. No evaluation can be communicated regarding pathology that was not visible in the image/video clips provided.

Thank you for this referral. If the clinical or image interpretation does not parallel your findings or if I can be of any further assistance please contact me.

**Nele Eley**, DVM, Dr. med. vet., DipECVDI  
European Specialist in Veterinary Diagnostic Imaging, Cert. Radiology,  
Senior lecturer University of Giessen, Germany, Veterinary Faculty, Department of Radiology  
Nele.Eley@sonopath.com