



PATIENT

Milo Mootoo

PRESENTING CLINICAL SIGNS

Coughing frequently, especially after exercise and at night. Grade 2-3 heart murmur. More prominent on the left side. Palpating trachea - coughs a lot. Need to r/o heart problem vs. tracheal collapse

SPECIES

Canine

RADIOGRAPHIC STUDY OF THE THORAX

Multiple right/left lateral and ventrodorsal views totaling 9 images available for review.

BREED

Shihtzu

RADIOGRAPHIC FINDINGS

The surrounding bony structures are within normal limits.

The extrathoracic soft tissues present homogeneous without abnormalities.

SEX

Male not neutered

The heart is of normal size and shape and there is no evidence of cardiac chamber or vascular enlargement. The pulmonary vasculature is within normal limits. The vertebral heart score is 9.8.

AGE

15 Years

The cranial mediastinum presents the expected soft tissue opacity. The mediastinal width is less than twice the width of the vertebral column at the same level.

Varying degrees of redundancy of the dorsal tracheal ligament and collapse are seen in the cervical trachea throughout the different projections.

INTERPRETED BY

Nele Eley, DVM
Dr. med. Vet. DipECVDI

The bronchial tree presents with thin walls and tapers uniformly towards the periphery as expected.

The lung parenchyma presents the expected architecture and opacity. The intrapulmonary vascular branching is seen up to the third order lung vessels.

HOSPITAL NAME

Truscott Animal
Hospital

The diaphragm is well delineated with even surface and the expected mild cranial bulging of the diaphragmatic cupola.

Mild gastric aerophagia is noted.

REFERRING VET

Medhat Meawad

RADIOGRAPHIC DIAGNOSIS

- Suspect dynamic tracheal disease.
- No radiographic evidence of cardiovascular pathology.
- Normal age related lung and bronchial tree.

INVOICE

48418

INTERPRETATION OF THE FINDINGS & FURTHER RECOMMENDATIONS

The radiographic findings suggest potential for dynamic tracheal disease. The radiographic presentation of the cardiac silhouette on the other hand is innocuous. There is no evidence of generalized cardiomegaly or specific chamber enlargement and no evidence of congestive heart failure.

DATE

11-16-21



PATIENT

Milo Mootoo

SPECIES

Canine

BREED

Shihtzu

SEX

Male not neutered

AGE

15 Years

INTERPRETED BY

Nele Eley, DVM
Dr. med. Vet. DipECVDI

HOSPITAL NAME

Truscott Animal
Hospital

REFERRING VET

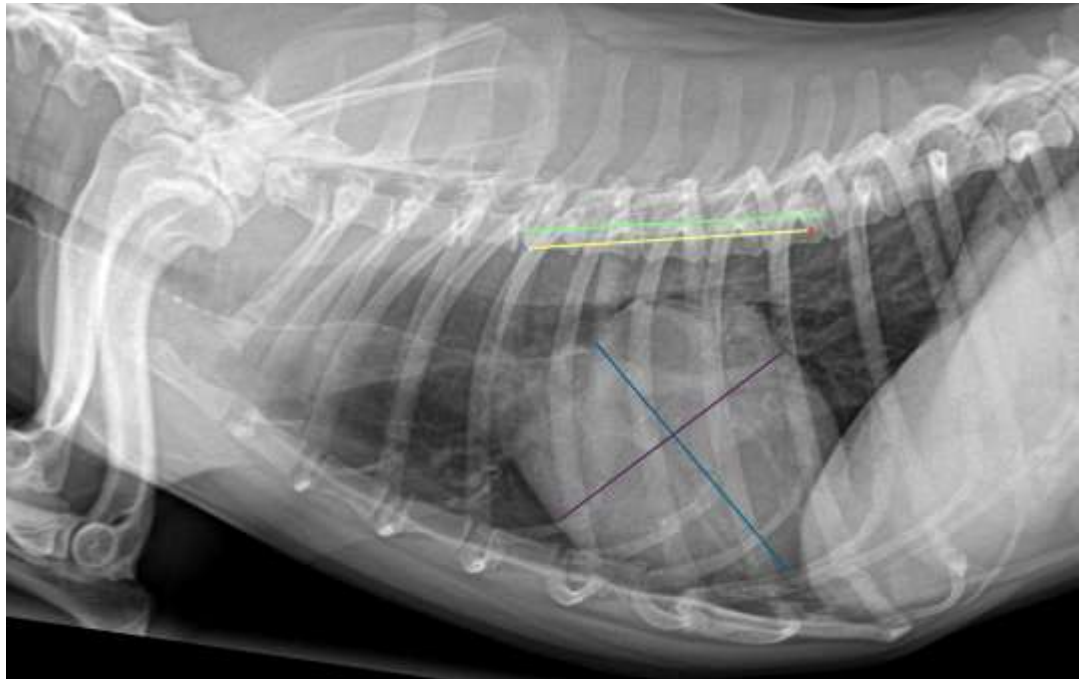
Medhat Meawad

INVOICE

48418

DATE

11-16-21



The information and recommendations provided are based on the images presented by the referring veterinarian. No evaluation can be communicated regarding pathology that was not visible in the image/video clips provided.

Thank you for this referral. If the clinical or image interpretation does not parallel your findings or if I can be of any further assistance please contact me.

Nele Eley, DVM, Dr. med. vet., DipECVDI
European Specialist in Veterinary Diagnostic Imaging, Cert. Radiology,
Senior lecturer University of Giessen, Germany, Veterinary Faculty, Department of Radiology
Nele.Eley@sonopath.com