



**PATIENT**

Friskies Dwinells

**PRESENTING CLINICAL SIGNS**

Approximately 1 year history of nasal congestion and purulent nasal discharge. Was unsuccessfully treated for several months with various antibiotics and steroids. Best results were seen recently with Doxycycline which Pt is still on. Discharge has stopped but congestion has continued. Owners are seeking direction on Medical vs Surgical treatment.

**SPECIES**

Feline

**COMPUTED TOMOGRAPHIC STUDY OF THE HEAD**

Plain and post contrast studies available for review.

**BREED**

DSH

**COMPUTED TOMOGRAPHIC FINDINGS**

The brain presents no deviation from normal anatomy and symmetry. The grey and white matter distinction and the neuroparenchymal attenuation are as expected. The distribution of contrast enhancement is within normal limits throughout the parenchyma and meninges. The ventricular system is non-dilated and within the limits of the expected volume and symmetry.

**SEX**

Female Spay

A moderate amount of fluid attenuating material is present within both nasal cavities as well as mucosal swelling. There is mild bilateral turbinate destruction. The right frontal sinus is almost completely filled with fluid attenuating material. Swelling of the mucosal lining is noted within the left frontal sinus. The nasal fundus presents irregular polypoid mucosal swelling which can be traced into the nasopharynx. No nasopharyngeal stenosis is present at this point.

**AGE**

4 Years

Both temporomandibular joints present congruent joint spaces with even subchondral bone surfaces and are considered within normal limits.

**INTERPRETED BY**

Nele Eley, DVM  
Dr. med. Vet. DipECVDI

Both tympanic bullae are aerated, the mucosal lining is not seen, the bony wall is smooth and thin. The external auditory meatuses present within normal limits.

**HOSPITAL NAME**

Bluegrass Veterinary  
Specialists

Both medial retropharyngeal and submandibular lymph nodes present mild symmetric enlargement.

The salivary glands present within normal limits.

The visible dentition is within normal limits.

**REFERRING VET**

Gover

**COMPUTED TOMOGRAPHIC DIAGNOSIS**

- Chronic bilateral mildly destructive rhinosinusitis with chronic nasopharyngitis and regional lymphadenitis.

**INVOICE**

48387

**INTERPRETATION OF THE FINDINGS & FURTHER RECOMMENDATIONS**

The CT study reveals mildly destructive bilateral rhinosinusitis. The changes within the nasal fundus and nasopharynx strongly suggest chronic inflammatory mucosal hyperplasia with no overt stenosis being present at this point. Infectious rhinitis such as bacterial, viral, or mixed is considered most likely. The changes are not typical for fungal rhinitis and neither typical for lymphoplasmacytic rhinitis even though these cannot be ruled out entirely. Further definition by means of rhinoscopy and sampling is recommended if not performed already.

**DATE**

11-16-21



**PATIENT**

Friskies Dwinells

**SPECIES**

Feline

**BREED**

DSH

**SEX**

Female Spay

**AGE**

4 Years

**INTERPRETED BY**

Nele Eley, DVM  
Dr. med. Vet. DipECVDI

**HOSPITAL NAME**

Bluegrass Veterinary  
Specialists

**REFERRING VET**

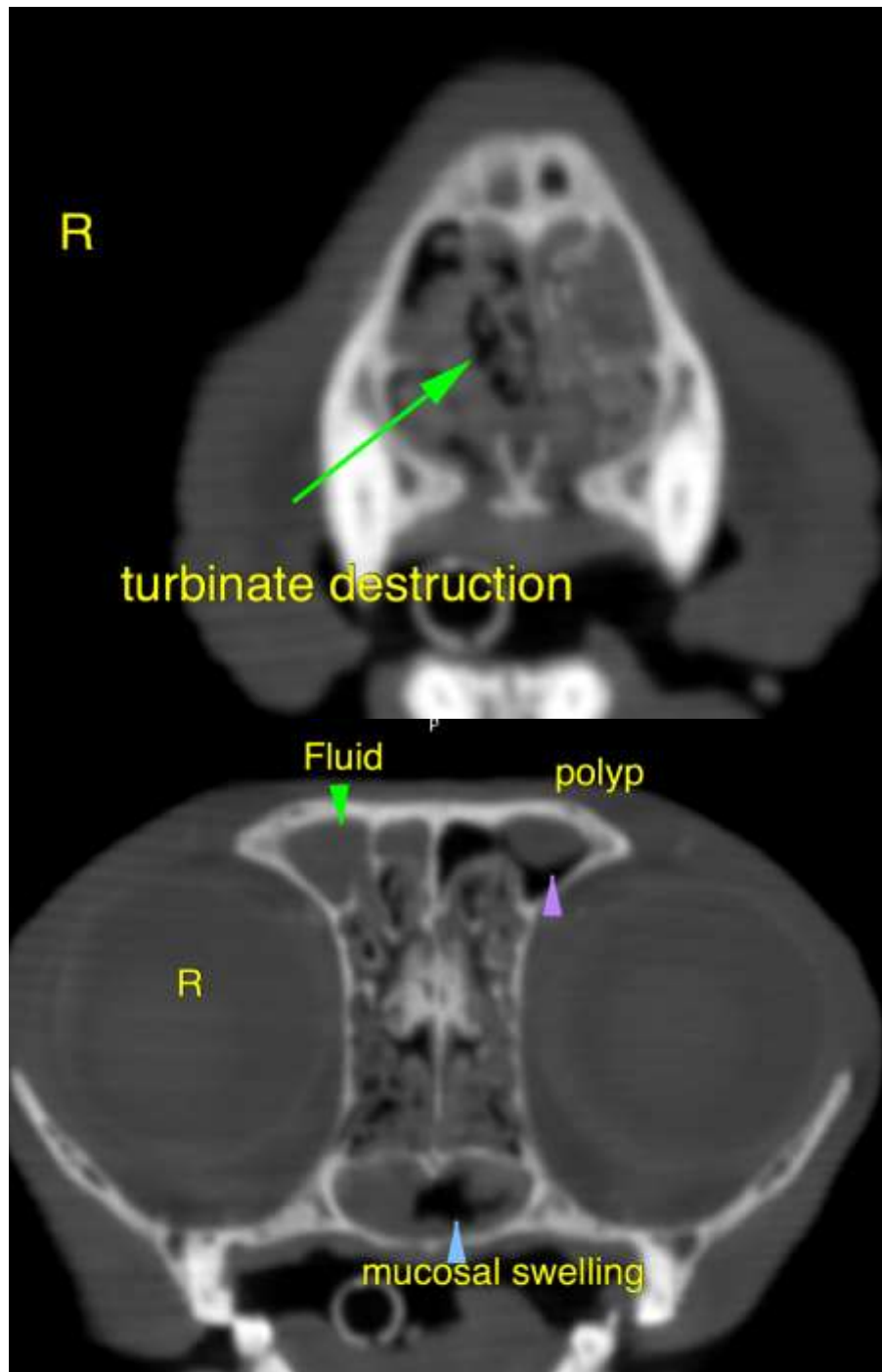
Gover

**INVOICE**

48387

**DATE**

11-16-21





**PATIENT**

Friskies Dwinells

**SPECIES**

Feline

**BREED**

DSH

**SEX**

Female Spay

**AGE**

4 Years

**INTERPRETED BY**

Nele Eley, DVM  
Dr. med. Vet. DipECVDI

**HOSPITAL NAME**

Bluegrass Veterinary  
Specialists

**REFERRING VET**

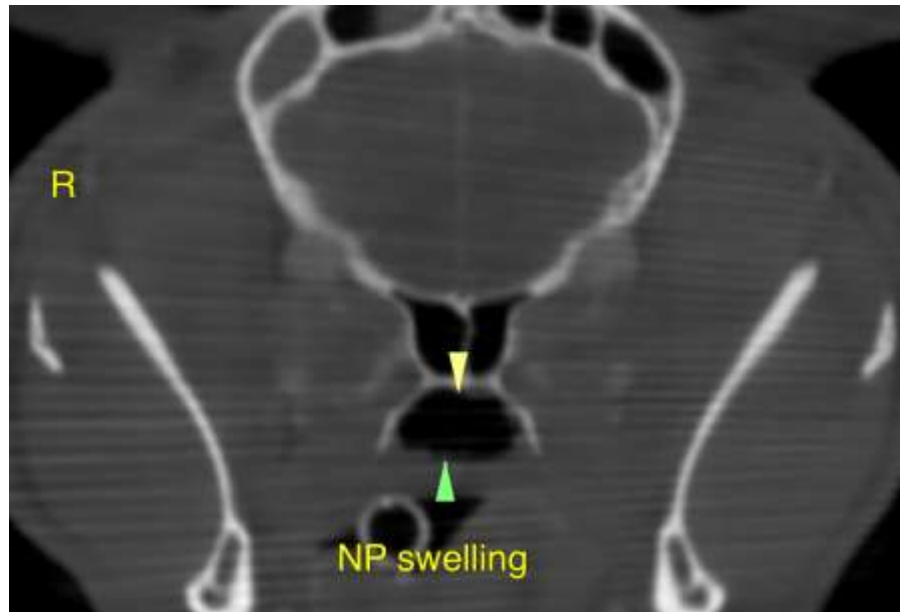
Gover

**INVOICE**

48387

**DATE**

11-16-21



The information and recommendations provided are based on the images presented by the referring veterinarian. No evaluation can be communicated regarding pathology that was not visible in the image/video clips provided.

Thank you for this referral. If the clinical or image interpretation does not parallel your findings or if I can be of any further assistance please contact me.

**Nele Eley**, DVM, Dr. med. vet., DipECVDI  
European Specialist in Veterinary Diagnostic Imaging, Cert. Radiology,  
Senior lecturer University of Giessen, Germany, Veterinary Faculty, Department of Radiology  
Nele.Eley@sonopath.com