



PATIENT

Bob Waters

PRESENTING CLINICAL SIGNS

coughing multiple times per day, especially after consuming water. Grade systolic heart murmur
Abnormal PE/Chem/CBC/UA Results: CBC/ Chemistry/ Urinalysis = no significant abnormalities

SPECIES

Canine

RADIOGRAPHIC STUDY OF THE THORAX

Right/left lateral and ventrodorsal views totaling 3 images available for review.

BREED

Pug Mix

RADIOGRAPHIC FINDINGS

Both elbow joints present moderate osteoarthritic changes.

The vertebral heart score is 11.4 which is within the upper reference range for pugs.

SEX

Neutered

The degree of pulmonary inflation is fair. No structural pulmonary lesions are seen.

Far cranial excursion of the diaphragm is seen.

AGE

14 Years

There is redundancy of the dorsal tracheal ligament in the cervical trachea on the right lateral image.

No evidence of mediastinal lymphadenomegaly is seen.

INTERPRETED BY

Nele Eley, DVM
Dr. med. Vet. DipECVDI

There is mild gastric aerophagia.

RADIOGRAPHIC DIAGNOSIS

- Radiographically normal heart.
- Redundant tracheal membrane.
- Poor pulmonary inflation presumably secondary to upper airway restriction.

HOSPITAL NAME

Q Street Animal
Hospital

INTERPRETATION OF THE FINDINGS & FURTHER RECOMMENDATIONS

The radiographic presentation of the cardiac silhouette is considered within age and breed related normal limits. Left atrial enlargement in general can cause coughing if there is a mass effect on the left mainstem bronchus; however, no radiographic evidence of left atrial enlargement is seen at this point.

REFERRING VET

Bretschneider

There is no evidence of structural lung pathology and no abnormal mediastinal widening noted.

INVOICE

48399

The redundancy of the dorsal tracheal ligament can be associated with dynamic tracheal disease. Concurrent brachycephalic upper airway syndrome, however, is likely and upper airway disease should be ruled out in this patient.

DATE

11-16-21



PATIENT

Bob Waters

SPECIES

Canine

BREED

Pug Mix

SEX

Neutered

AGE

14 Years

INTERPRETED BY

Nele Eley, DVM
Dr. med. Vet. DipECVDI

HOSPITAL NAME

Q Street Animal
Hospital

REFERRING VET

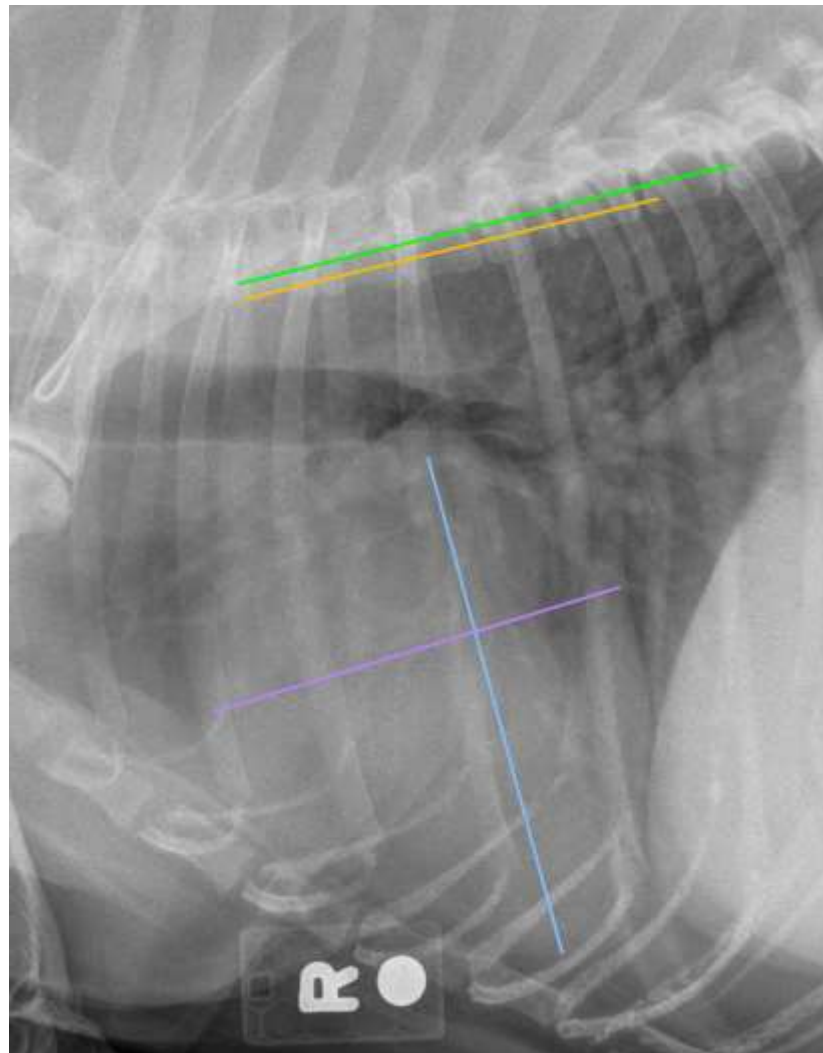
Bretschneider

INVOICE

48399

DATE

11-16-21



The information and recommendations provided are based on the images presented by the referring veterinarian. No evaluation can be communicated regarding pathology that was not visible in the image/video clips provided.

Thank you for this referral. If the clinical or image interpretation does not parallel your findings or if I can be of any further assistance please contact me.

Nele Eley, DVM, Dr. med. vet., DipECVDI
European Specialist in Veterinary Diagnostic Imaging, Cert. Radiology,
Senior lecturer University of Giessen, Germany, Veterinary Faculty, Department of Radiology
Nele.Eley@sonopath.com