



PATIENT

Zelda Langfeld,
Heather

PRESENTING CLINICAL SIGNS

-Hx suspect IMPA (6mth history pain) -Swelling under mandible - r/o lymphadenopathy, abscess, sialoadenitis, neoplasia, FB, other

SPECIES

Canine

COMPUTED TOMOGRAPHIC STUDY OF THE HEAD

Plain and post contrast studies available for review.

BREED

Cavalier King Charles
Spaniel

The patient has a brachycephalic head conformation with dome shaped calvarium and shortening of the facial bones.

Caudal occipital malformation with craniocervical stenosis is noted. The conformation of the brain is typical for a brachycephalic dog. Mild and symmetric dilation of the lateral ventricles of the brain is seen.

SEX

Female

The submandibular and retropharyngeal lymph nodes present within normal limits.

The mandibular and parotid salivary glands present within normal limits as well.

AGE

2 Years

The tympanic bullae and external auditory meatuses are within normal limits.

Mild multifocal periodontal disease is noted in all quadrants.

INTERPRETED BY

Nele Eley, DVM
Dr. med. Vet. DipECVDI

COMPUTED TOMOGRAPHIC DIAGNOSIS

- Normal age and breed specific CT presentation of the head with no evidence of submandibular mass effect.

HOSPITAL NAME

Animal Health
Partners

INTERPRETATION OF THE FINDINGS & FURTHER RECOMMENDATIONS

The CT findings are considered within age and breed related normal limits. No evidence of regional lymphadenomegaly, sialadenopathy, neoplasia, or foreign material is noted.

REFERRING VET

Dr. Shannon
Westgrath

INVOICE

55188

DATE

11-15-22



PATIENT

Zelda Langfeld,
Heather

SPECIES

Canine

BREED

Cavalier King Charles
Spaniel

SEX

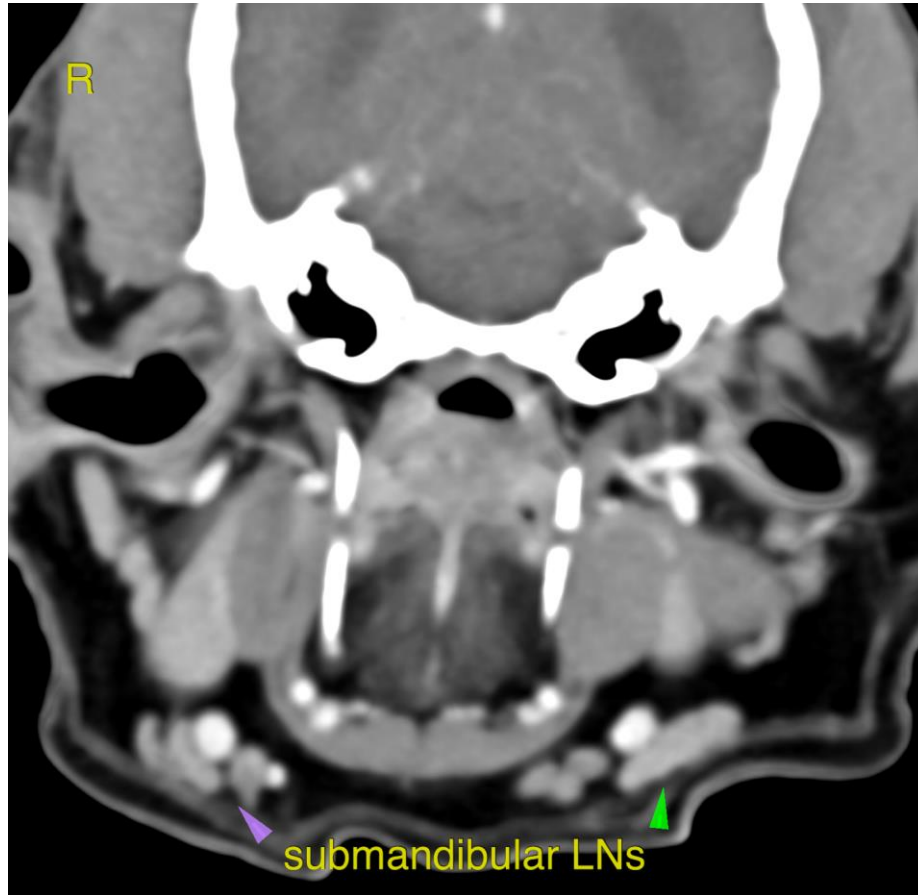
Female

AGE

2 Years

INTERPRETED BY

Nele Eley, DVM
Dr. med. Vet. DipECVDI



HOSPITAL NAME

Animal Health
Partners

The information and recommendations provided are based on the images presented by the referring veterinarian/sonographer. No evaluation can be communicated regarding pathology that was not visible in the image/video clips provided.

Thank you for this referral. If the clinical or image interpretation does not parallel your findings or if I can be of any further assistance please contact me.

REFERRING VET

Dr. Shannon
Westgrath

Nele Eley, DVM, Dr. med. vet., DipECVDI
European Specialist in Veterinary Diagnostic Imaging, Cert. Radiology,
Senior lecturer University of Giessen, Germany, Veterinary Faculty, Department of Radiology
Nele.Eley@sonopath.com

INVOICE

55188

DATE

11-15-22