



PATIENT

Chickpea Cimaglia

PRESENTING CLINICAL SIGNS

Left ocular changes with history of nasal discharge and possibly polyp. possible VBO, as well

SPECIES

Feline

COMPUTED TOMOGRAPHIC STUDY OF THE HEAD

Post-contrast study available for review.

BREED

DSH

COMPUTED TOMOGRAPHIC FINDINGS

The brain presents no deviation from normal anatomy and symmetry. The grey and white matter distinction and the neuroparenchymal attenuation are as expected. The distribution of contrast enhancement is within normal limits throughout the parenchyma and meninges. The ventricular system is non-dilated and within the limits of the expected volume and symmetry.

SEX

FS

Thin and smoothly folded conchae and turbinates with even smooth mucosal lining.

Both temporomandibular joints present congruent joint spaces with even subchondral bone surfaces and are considered within normal limits.

AGE

1 Year, 3 Months

There is no evidence that a ventral bulla osteotomy had been performed before. Both tympanic bullae are aerated. The osseous lining is thin walled. Small otoliths are seen within the lumen of the tympanic bullae which usually is a finding that has on clinical significance. Mild irregularity of the ear canal wall's epithelial lining is seen accentuating the right side more so than the left side.

INTERPRETED BY

Nele Eley, DVM
Dr. med. Vet. DipECVDI

The left medial retropharyngeal lymph node is mildly enlarged with maintained short-to-long-axis-ratio and contrast enhancement pattern.

The salivary glands present within normal limits.

HOSPITAL NAME

Animal Surgical
Center

The visible dentition is within normal limits.

COMPUTED TOMOGRAPHIC DIAGNOSIS

- Structurally normal CT study of the nasal cavities and paranasal sinuses.
- No evidence of otitis media.
- Mild bilateral otitis externa.
- Left sided medial retropharyngeal lymphadenomegaly.

REFERRING VET

Islip AH

INTERPRETATION OF THE FINDINGS & FURTHER RECOMMENDATIONS

At this time, there is no evidence of otitis media. There appears to be mild bilateral otitis externa, right more than left.

INVOICE

48370

The left medial retropharyngeal lymphadenomegaly is suggestive for reactive hyperplasia and may be a consequence of the ocular disease.

DATE

11-15-21

No structural abnormality in the eye and eye area is seen.



PATIENT

Chickpea Cimaglia

SPECIES

Feline

BREED

DSH

SEX

FS

AGE

1 Year, 3 Months

INTERPRETED BY

Nele Eley, DVM
Dr. med. Vet. DipECVDI

HOSPITAL NAME

Animal Surgical
Center

REFERRING VET

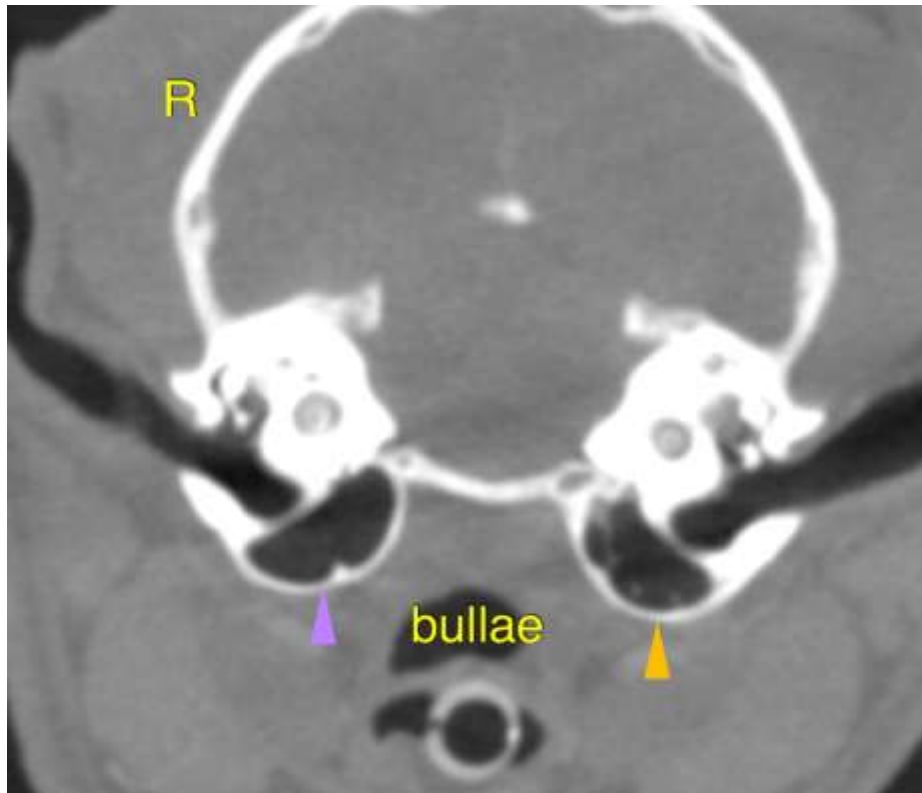
Islip AH

INVOICE

48370

DATE

11-15-21



The information and recommendations provided are based on the images presented by the referring veterinarian. No evaluation can be communicated regarding pathology that was not visible in the image/video clips provided.

Thank you for this referral. If the clinical or image interpretation does not parallel your findings or if I can be of any further assistance please contact me.

Nele Eley, DVM, Dr. med. vet., DipECVDI
European Specialist in Veterinary Diagnostic Imaging, Cert. Radiology,
Senior lecturer University of Giessen, Germany, Veterinary Faculty, Department of Radiology
Nele.Eley@sonopath.com