



**PATIENT**

Pique Abdul Ghani

**PRESENTING CLINICAL SIGNS**

last time a rubber tube he swallowed , again rubber is missing please see old report of piquet , to rule put FB  
Abnormal PE/Chem/CBC/UA Results: normal

**SPECIES**

Feline

**RADIOGRAPHIC STUDY OF THE ABDOMEN**

Right lateral and ventrodorsal views totaling 2 images available for review.

**BREED**

Himalaya

**RADIOGRAPHIC FINDINGS**

The surrounding bony structures are within normal limits.

**SEX**

MN

No abnormalities of the extraabdominal soft tissues are noted. The abdominal wall is smooth and thin.

The serosal detail is maintained throughout the peritoneal and retroperitoneal space.

The liver is appropriate in position, size and presents uniform opacity.

**AGE**

3 Years, 6 Months

The splenic head is in the anticipated position and within normal limits for size and opacity. The splenic tail is not seen.

**INTERPRETED BY**

Nele Eley, DVM  
Dr. med. Vet. DipECVDI

Both kidneys are seen and present with normal size, shape, delineation and opacity. The urinary bladder is in its anticipated position. No radiopaque calculi are noted throughout the upper and lower urinary tract.

The stomach contains a mild amount of fluid and gas. No evidence of foreign material is seen within the stomach.

**HOSPITAL NAME**

The Veterinary  
Surgery

The small intestinal loops are evenly distributed throughout the mid abdomen without evidence of abnormal dilation, plication, or radiopaque foreign material.

A rectangular shaped well delineated structure with soft tissue opaque margins and hollow lumen of 3.5 cm length and 7mm diameter is seen within the descending colon level with the 6<sup>th</sup> lumbar vertebra.

**REFERRING VET**

Dr. Samad Khan

**RADIOGRAPHIC DIAGNOSIS**

- Foreign material within the descending colon.
- No evidence of small intestinal ileus.

**INVOICE**

48334

**INTERPRETATION OF THE FINDINGS & FURTHER RECOMMENDATIONS**

The foreign material / rubber tube appears to have passed the natural way without causing mechanical ileus or peritonitis. Further imaging is only indicated in case of recurring clinical signs.

**DATE**

11-14-21



**PATIENT**

Pique Abdul Ghani

**SPECIES**

Feline

**BREED**

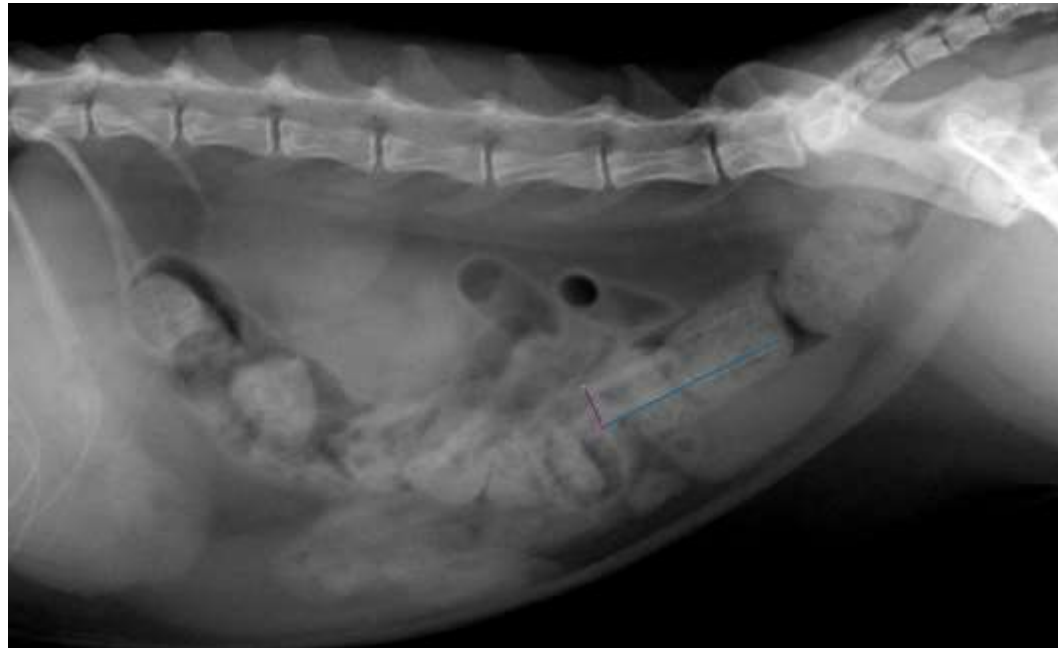
Himalaya

**SEX**

MN

**AGE**

3 Years, 6 Months



**INTERPRETED BY**

Nele Eley, DVM  
Dr. med. Vet. DipECVDI

The information and recommendations provided are based on the images presented by the referring veterinarian. No evaluation can be communicated regarding pathology that was not visible in the image/video clips provided.

Thank you for this referral. If the clinical or image interpretation does not parallel your findings or if I can be of any further assistance please contact me.

**HOSPITAL NAME**

The Veterinary  
Surgery

**Nele Eley**, DVM, Dr. med. vet., DipECVDI  
European Specialist in Veterinary Diagnostic Imaging, Cert. Radiology,  
Senior lecturer University of Giessen, Germany, Veterinary Faculty, Department of Radiology  
Nele.Eley@sonopath.com

**REFERRING VET**

Dr. Samad Khan

**INVOICE**

48334

**DATE**

11-14-21