



PATIENT

Arwen Crabtree

SPECIES

Dog

BREED

Dachshund

SEX

Female

AGE

4Y

WEIGHT

11.8

INTERPRETED BY

Nele Eley (Ondreka),
DVM Dr. med. vet.,
DipECVDI

IMAGING PERFORMED BY

DeeDee Vasquez

HOSPITAL NAME

Petroglyph Animal
Hospital

REFERRING VET

Viviana Sanchez

INVOICE

72614

DATE

11-13-25

PRESENTING CLINICAL SIGNS

Bile acids performed at primary vet. Suspect for portosystemic liver shunt.
Abnormal PE/Chem/CBC/UA Results: Elevated ALT

COMPUTED TOMOGRAPHIC STUDY OF THE ABDOMEN

Plain and post contrast studies are available for review.

COMPUTED TOMOGRAPHIC FINDINGS

Motion related blur is seen in the cranial abdomen close to the diaphragm.

The CT study reveals a single extrahepatic portosystemic shunt coursing from the splenic vein through the phrenic vein into the caudal vena cava level with the diaphragm. Shunt diameter is approximately 5mm. Portal vein diameter decreases abruptly cranial to the shunt origin.

The liver is reduced in size with reduced portal vein perfusion and branching.

The kidneys are mildly enlarged with mild renal microliths. No evidence of obstruction is noted.

No evidence of urinary bladder calculi is seen.

The other abdominal organs are unremarkable.

COMPUTED TOMOGRAPHIC DIAGNOSIS

- Single congenital extrahepatic portosystemic shunt: splenophrenic shunt.
- Mild microhepatica and compensatory renomegaly.
- Mild renal microlithiasis -likely ammonium urate.

INTERPRETATION OF FINDINGS & FURTHER RECOMMENDATIONS

The CT findings are consistent with a congenital portosystemic shunt. The shunt is draining blood from the splenic vein via the phrenic vein into the caudal vena cava.

Mild microhepatica and renal enlargement with microliths are noted.

Surgical intervention and correction of the portosystemic shunt should be considered in consultation with a specialized surgeon. Medical and dietetic management should be pursued in the meantime.



PATIENT

Arwen Crabtree

SPECIES

Dog

BREED

Dachshund

SEX

Female

AGE

4Y

WEIGHT

11.8

INTERPRETED BY

Nele Eley (Ondreka),
DVM Dr. med. vet.,
DipECVDI

IMAGING PERFORMED BY

DeeDee Vasquez

HOSPITAL NAME

Petroglyph Animal
Hospital

REFERRING VET

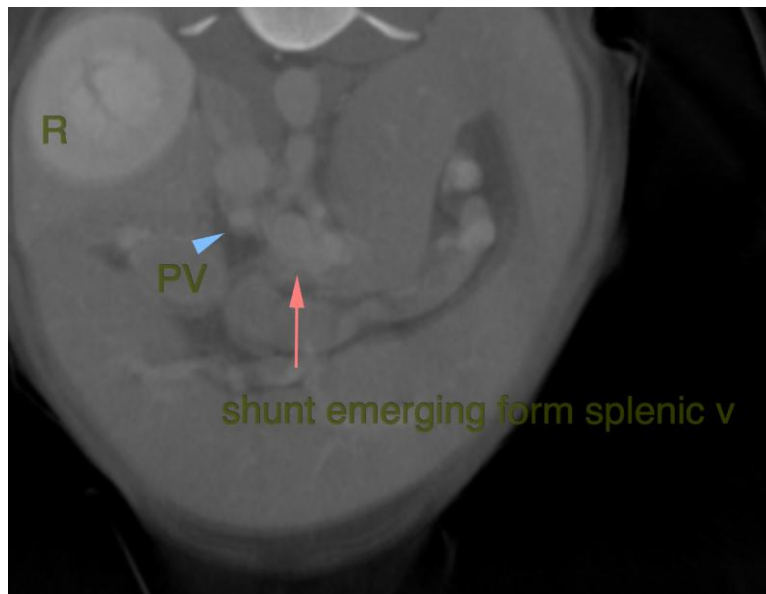
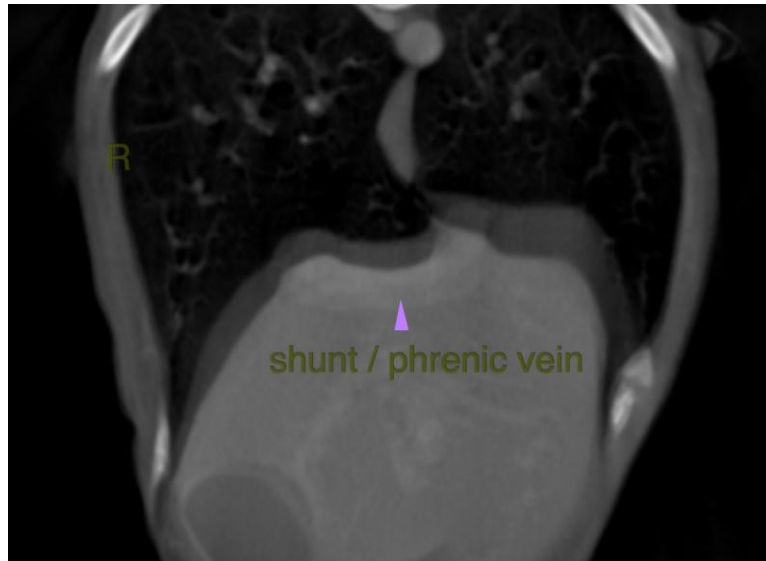
Viviana Sanchez

INVOICE

72614

DATE

11-13-25



The information and recommendations provided are based on the images presented by the referring veterinarian. No evaluation can be communicated regarding pathology that was not visible in the image/video clips provided.

Thank you for this referral. If the clinical or image interpretation does not parallel your findings or if I can be of any further assistance please contact me.

Nele Eley (Ondreka), DVM, Dr. med. vet., DipECVDI
European Specialist in Veterinary Diagnostic Imaging, Cert. Radiology,
Senior lecturer University of Giessen/Germany, Veterinary Faculty, Department of Radiology.
info@sonopath.com