



PATIENT

Smokey Woloson

PRESENTING CLINICAL SIGNS

Patient presented for toe touching lame with non weight bearing on right pelvic limb. Patient was previously diagnosed with hip dysplasia Senior bloodwork pending

SPECIES

Canine

RADIOGRAPHIC FINDINGS

The patient is obese.

BREED

Newfoundland

Pelvis

Dirt fur artifact is superimposed onto the medioproximal right thigh.

Disuse atrophy of the musculature and bones is seen in both hind limbs. The degree of muscle atrophy appears to be more pronounced on the left compared with the right side.

SEX

MN

Moderate joint space divergence, subchondral bone sclerosis, and circumferential femoral head as well as caudolateral curvilinear femoral neck osteophytes are seen in both coxofemoral joints with significantly reduced femoral head coverage.

AGE

4

Stifles

Moderate to severe articular swelling of the right stifle joint is seen with mild cranial thrust of the tibia and proximal displacement of the popliteal sesamoid bone. There is a moderate amount of periarticular osteophytes accentuating the femoral trochlea, distal pole of the patella, and cranial margin of the tibial plateau.

INTERPRETED BY

Nele Eley, DVM
Dr. med. Vet. DipECVDI

Mild articular swelling of the left stifle joint is seen as well.

RADIOGRAPHIC DIAGNOSIS

- Moderate bilateral canine hip dysplasia with secondary osteoarthritis.
- Disuse atrophy in both hind limbs - right more than left.
- Moderate right stifle osteoarthritis with radiographic evidence of cranial cruciate ligament failure.
- Mild left stifle effusion.

HOSPITAL NAME

Boca Park Animal Hospital

INTERPRETATION OF THE FINDINGS & FURTHER RECOMMENDATIONS

Dr. Corinna Gorgon

The radiographic findings suggest presence of failure of the cranial cruciate ligament function in the right stifle joint with concurrent moderate osteoarthritic changes. Correlate with the palpation and consider surgical intervention in order to address the presumed biomechanical instability and prevent further damage to the articular structures.

INVOICE

48327

DATE

11-13-21



PATIENT

Smokey Woloson

SPECIES

Canine

BREED

Newfoundland

SEX

MN

AGE

4

INTERPRETED BY

Nele Eley, DVM
Dr. med. Vet. DipECVDI

HOSPITAL NAME

Boca Park Animal
Hospital

REFERRING VET

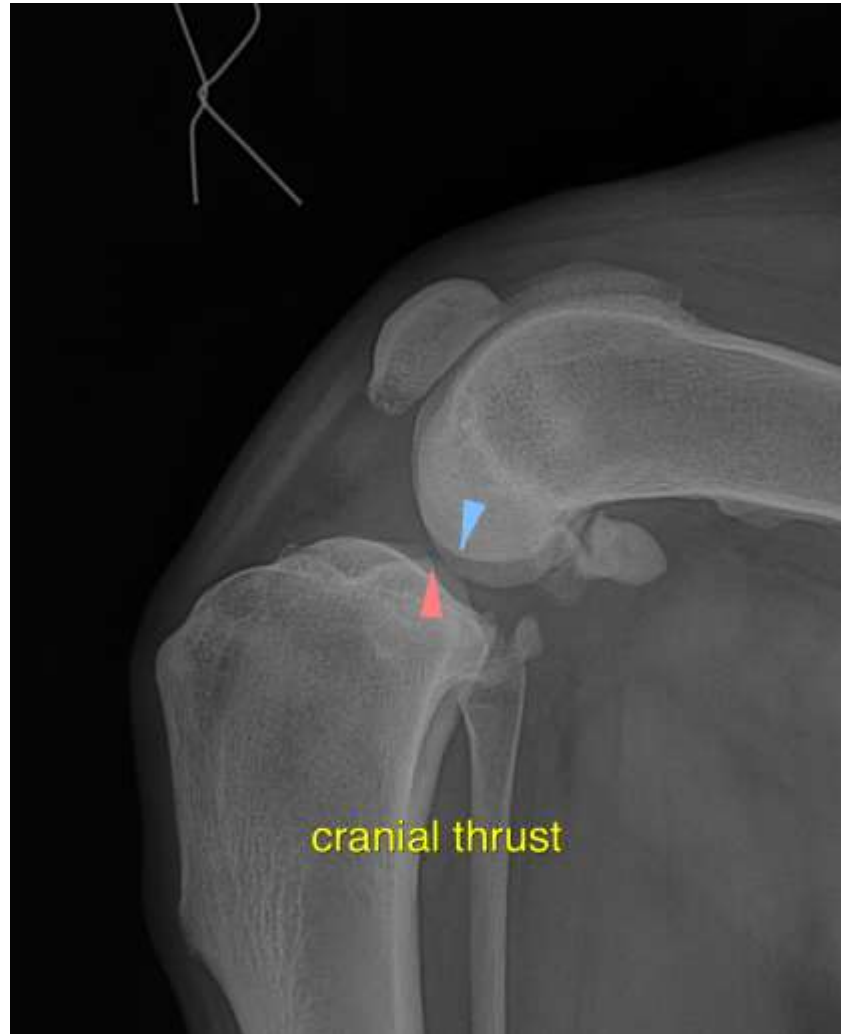
Dr. Corinna Gorgon

INVOICE

48327

DATE

11-13-21



The information and recommendations provided are based on the images presented by the referring veterinarian. No evaluation can be communicated regarding pathology that was not visible in the image/video clips provided.

Thank you for this referral. If the clinical or image interpretation does not parallel your findings or if I can be of any further assistance please contact me.

Nele Eley, DVM, Dr. med. vet., DipECVDI
European Specialist in Veterinary Diagnostic Imaging, Cert. Radiology,
Senior lecturer University of Giessen, Germany, Veterinary Faculty, Department of Radiology
Nele.Eley@sonopath.com