

**PATIENT**

Chubbles Eagan

SPECIES

Feline

BREED

American Shorthair

SEX

Male Neutered

AGE

13 Years

INTERPRETED BYNele Eley, DVM
Dr. med. Vet. DipECVDF**HOSPITAL NAME**Belvedere Veterinary
Center**REFERRING VET**

Dr. Brendan Moulder

INVOICE

48363

DATE

11-13-21

PRESENTING CLINICAL SIGNS

Originally diagnosed with changes in the spleen concerning for infiltrative neoplasia (round cell tumor, lymphoma, mast cell tumor, multiple myeloma), large/irregular lymph nodes (concerning for lymphadenitis), several hyperechoic liver nodules and a diffusely prominent pancreas in February of 2021 on ultrasound after an unclassified anemia and weight loss were noted on presurgical examination ahead of a planned dental. Os considered abdominal explore at that time but decided not to pursue. Today, p has prominent organomegally, suspected spleen.

RADIOGRAPHIC STUDY OF THE ABDOMEN

Right/left lateral and ventrodorsal views totaling 4 images available for review.

RADIOGRAPHIC FINDINGS

Severe generalized splenomegaly is seen.

There also appears to be mildly reduced abdominal serosal detail.

The liver, kidneys, and gastrointestinal tract present within normal limits.

There is mild spondylosis between L6 and L7 as well as L7 and S1.

RADIOGRAPHIC DIAGNOSIS

- Severe generalized splenomegaly.
- Mildly reduced serosal detail.

INTERPRETATION OF THE FINDINGS & FURTHER RECOMMENDATIONS

The primary differential diagnosis for such severe enlargement of the spleen is diffuse neoplastic infiltrate with round cells or other hematopoietic neoplasia. Fine needle aspiration is required for further definition. Abdominal ultrasound could be repeated in order to rule out other organ involvement. As per the history, abdominal lymphadenomegaly is a potential as well.

The reduced serosal detail may simply be due to crowding of the abdominal organs. Mild peritoneal effusion cannot be ruled out entirely.



PATIENT

Chubbles Eagan

SPECIES

Feline

BREED

American Shorthair

SEX

Male Neutered

AGE

13 Years

INTERPRETED BY

Nele Eley, DVM
Dr. med. Vet. DipECVDI

HOSPITAL NAME

Belvedere Veterinary
Center

REFERRING VET

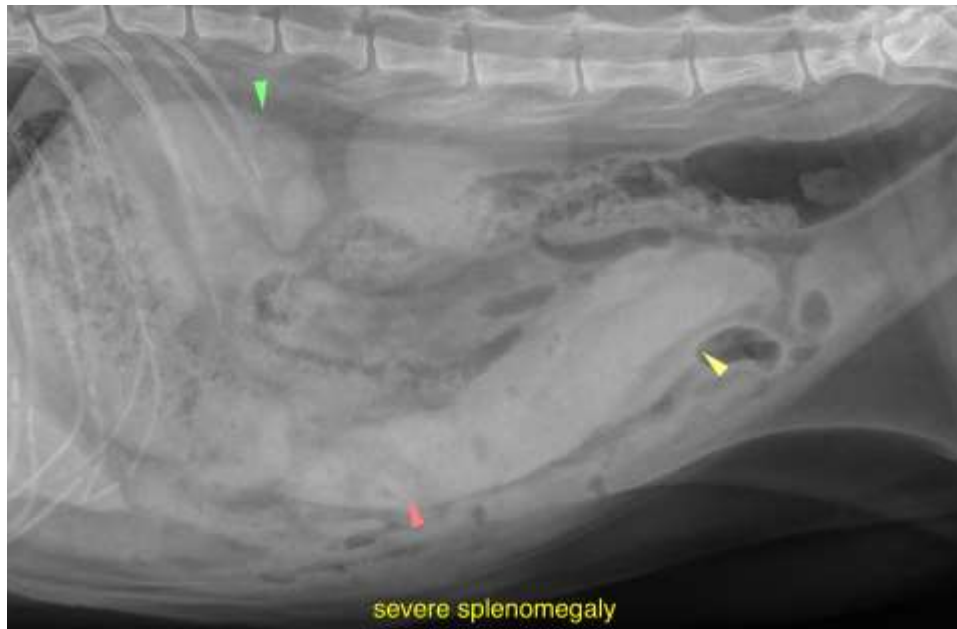
Dr. Brendan Moulder

INVOICE

48363

DATE

11-13-21



The information and recommendations provided are based on the images presented by the referring veterinarian. No evaluation can be communicated regarding pathology that was not visible in the image/video clips provided.

Thank you for this referral. If the clinical or image interpretation does not parallel your findings or if I can be of any further assistance please contact me.

Nele Eley, DVM, Dr. med. vet., DipECVDI
European Specialist in Veterinary Diagnostic Imaging, Cert. Radiology,
Senior lecturer University of Giessen, Germany, Veterinary Faculty, Department of Radiology
Nele.Eley@sonopath.com