SonoPath Teleradiology

EDUCATIONAL TELECONSULTATION SERVICES™

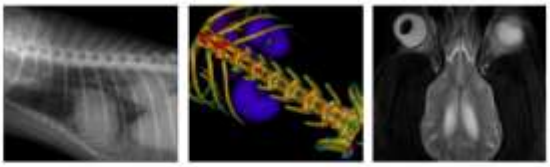

SonoPath.com
1-800-838-4268 info@sonopath.com

PATIENT

Chloe Tate

SPECIES

Ca

BREED

Terrier Mix

SEX

FS

AGE

8

INTERPRETED BY

Nele Eley, DVM
Dr. med. Vet. DipECVDI

HOSPITAL NAME

Torch Lake
Veterinary Clinic

REFERRING VET

Adrianne Waffle

INVOICE

48323

DATE

11-13-21

PRESENTING CLINICAL SIGNS

Hx of lethargy, inappetance, and pyrexia. Same symptoms treated in Arizona a month ago with carprofen and dexamethason (4 mg IM) Currently on enrofloxacin and clavamox and fever reduced from 104.6 on initial visit to 102.7 this visit. Bloodwork shows mildly elevated liver value (increased from bloodwork previously). CPL neg. Abdominal US unremarkable

RADIOGRAPHIC STUDY OF THE THORAX

Right/left lateral and ventrodorsal views totaling 3 images available for review.

RADIOGRAPHIC FINDINGS

Moderate bilateral shoulder osteoarthritis is seen.

The extrathoracic soft tissues present homogeneous without abnormalities.

The heart is of normal size and shape and there is no evidence of cardiac chamber or vascular enlargement. The pulmonary vasculature is within normal limits.

The cranial mediastinum presents the expected soft tissue opacity. The mediastinal width is less than twice the width of the vertebral column at the same level. No evidence of mediastinal lymphadenomegaly is seen.

The trachea is normal in diameter and presents the anticipated course. The luminal outline of the trachea is smooth.

Several soft tissue opaque interstitial consolidations of approximately 5mm diameter are superimposed onto the cranial lung field. The lung presents a mild generalized bronchointerstitial pattern. No evidence of pleural effusion is seen.

The diaphragm is well delineated with even surface and the expected mild cranial bulging of the diaphragmatic cupola.

The radiographic presentation of the liver is within normal limits.

The stomach is post-prandial.

RADIOGRAPHIC DIAGNOSIS

- Interstitial pulmonary nodules with bronchointerstitial lung pattern.
- Shoulder osteoarthritis - unrelated to the reason of clinical presentation.

INTERPRETATION OF THE FINDINGS & FURTHER RECOMMENDATIONS

The radiographic study reveals ill-defined small interstitial opacities in combination with a bronchointerstitial lung pattern. With the pertinent history, granulomatous pneumonia such as due to fungal, mycobacterial, or less likely bacterial infection is a potential differential diagnosis. The possibility of secondary neoplasia of the lung such as sarcoma with multifocal distribution cannot be ruled out entirely and further definition by means of airway endoscopy with airway sampling and testing for valley fever could be considered.

SonoPath Teleradiology

EDUCATIONAL TELECONSULTATION SERVICES™

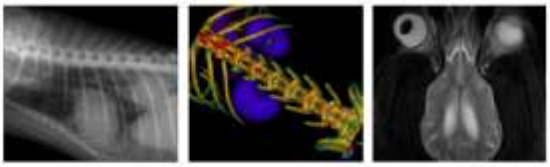

SonoPath.com
1-800-838-4268 info@sonopath.com

PATIENT

Chloe Tate

SPECIES

Ca

BREED

Terrier Mix

SEX

FS

AGE

8

INTERPRETED BY

Nele Eley, DVM
Dr. med. Vet. DipECVDI

HOSPITAL NAME

Torch Lake
Veterinary Clinic

REFERRING VET

Adrianne Waffle

INVOICE

48323

DATE

11-13-21

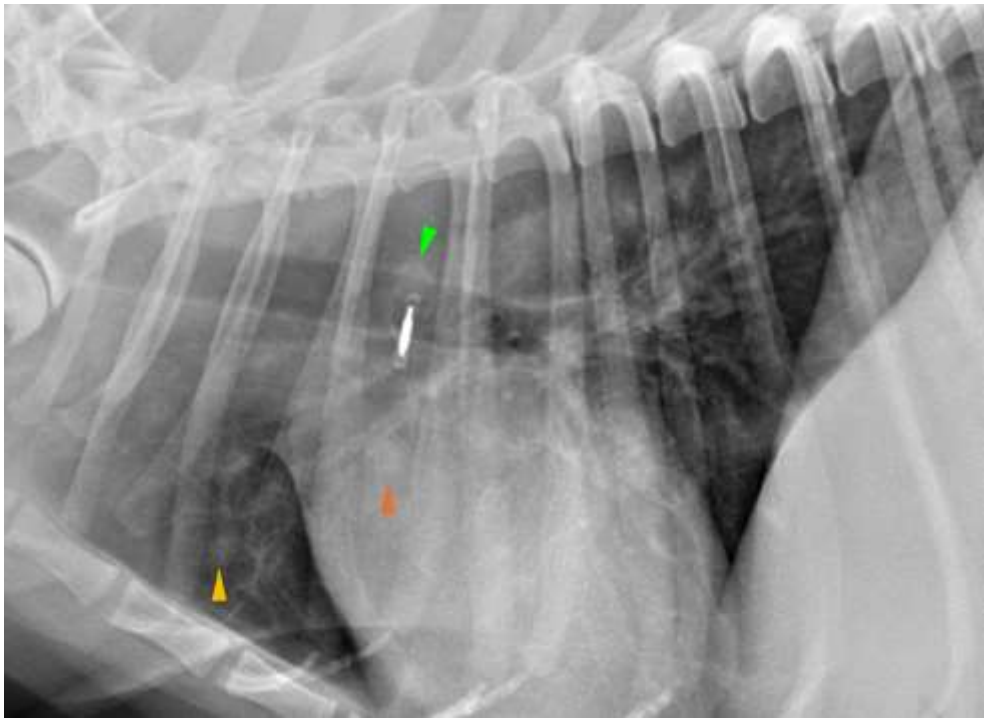

The information and recommendations provided are based on the images presented by the referring veterinarian. No evaluation can be communicated regarding pathology that was not visible in the image/video clips provided.

Thank you for this referral. If the clinical or image interpretation does not parallel your findings or if I can be of any further assistance please contact me.

Nele Eley, DVM, Dr. med. vet., DipECVDI
European Specialist in Veterinary Diagnostic Imaging, Cert. Radiology,
Senior lecturer University of Giessen, Germany, Veterinary Faculty, Department of Radiology
Nele.Eley@sonopath.com