

**PATIENT**

Raya Burnstick

PRESENTING CLINICAL SIGNS

since the time owner adopted puppy is vomiting after eating and losing weight, still active, no diarrhea, defecating fine
Abnormal PE/Chem/CBC/UA Results: none

SPECIES

Canine

RADIOGRAPHIC STUDY OF THE THORAX

Right/left lateral and dorsoventral views totaling 3 images available for review.

BREED

GSD

RADIOGRAPHIC FINDINGS

Severe generalized dilation of the cervical and thoracic esophagus is seen without evidence of diverticulum formation or stricture.

SEX

F

The trachea and heart base are deviated ventrally. Mild rightward deviation of the trachea can be seen in the orthogonal view which is a normal finding. The lateral outline of the aortic arch is seen to the left of the midline on the orthogonal view as well.

AGE

10 Weeks

At this point, there appears to be no evidence of aspiration pneumonia. The lung and bronchial tree are considered within age related normal limits.

The abdominal serosal detail is reduced which is considered within normal limits with reference to the patient's age.

INTERPRETED BY

Nele Eley, DVM
Dr. med. Vet. DipECVDI

A small umbilical hernia is seen in the abdominal ventrum.

RADIOGRAPHIC DIAGNOSIS

- Generalized megaesophagus without evidence of concurrent aspiration pneumonia.
- Aortic arch seen in its anticipated position to the left of the midline.
- Reduced serosal detail - within age related normal limits.
- Small umbilical hernia.

HOSPITAL NAME

Edmonton West
Animal Hospital &
Spay/Neuter Centre

INTERPRETATION OF THE FINDINGS & FURTHER RECOMMENDATIONS

Based on the radiographic findings, persistent right aortic arch can be ruled out. Other type of constricting vascular ring anomaly is thought very unlikely based on the presence of generalized esophageal dilation as well. Congenital megaesophagus is considered by far most likely differential diagnosis. At this point, there is no evidence of aspiration pneumonia; however, the patient is certainly at an increased risk of aspiration.

REFERRING VET

Sumeet Sharma

INVOICE

48297

DATE

11-12-21



PATIENT

Raya Burnstick

SPECIES

Canine

BREED

GSD

SEX

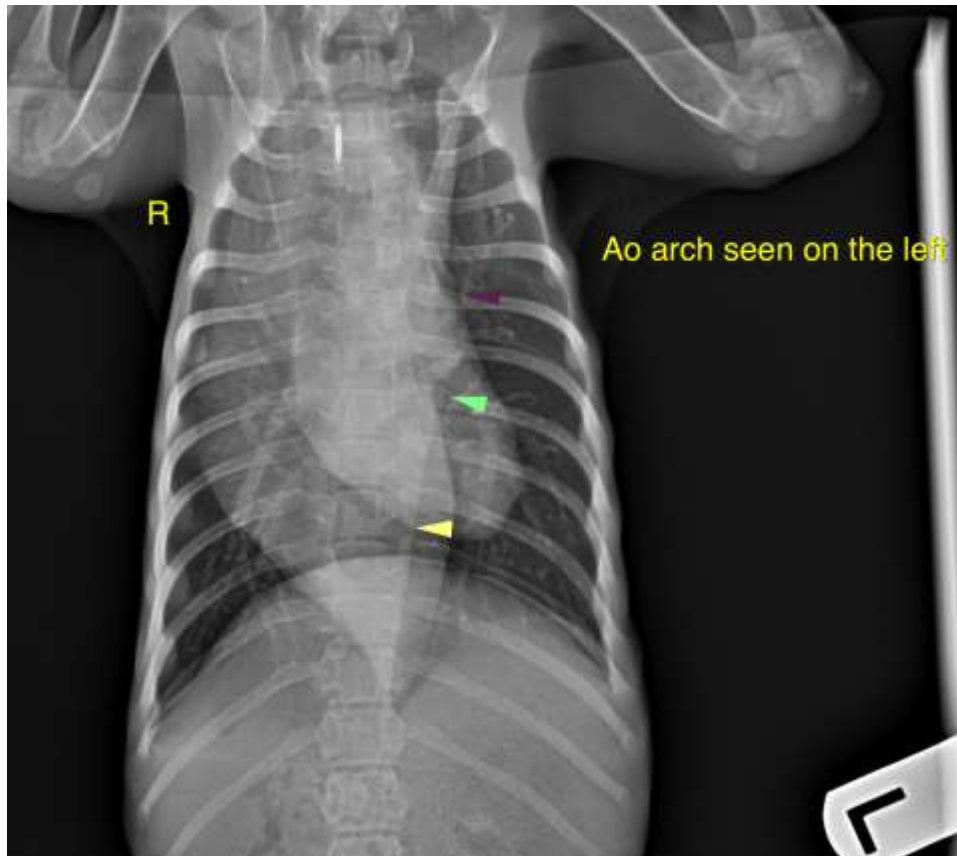
F

AGE

10 Weeks

INTERPRETED BY

Nele Eley, DVM
Dr. med. Vet. DipECVDI



HOSPITAL NAME

Edmonton West
Animal Hospital &
Spay/Neuter Centre

The information and recommendations provided are based on the images presented by the referring veterinarian. No evaluation can be communicated regarding pathology that was not visible in the image/video clips provided.

Thank you for this referral. If the clinical or image interpretation does not parallel your findings or if I can be of any further assistance please contact me.

REFERRING VET

Sumeet Sharma

Nele Eley, DVM, Dr. med. vet., DipECVDI
European Specialist in Veterinary Diagnostic Imaging, Cert. Radiology,
Senior lecturer University of Giessen, Germany, Veterinary Faculty, Department of Radiology
Nele.Eley@sonopath.com

INVOICE

48297

DATE

11-12-21