


PATIENT PRESENTING CLINICAL SIGNS

Sammy Reynolds Suspected congenital abnormality involving the left front dew claw noted at 9 week new patient exam. The dew claw curls under the paw and the patient walks on the dew claw and lateral aspect of the paw. We were planning on removing some of the dew claw at time of neuter until these x-rays were taken today and I realized that there are radial, ulnar, carpal, and digit abnormalities!

SPECIES Abnormal PE/Chem/CBC/UA Results: See above. I also have a picture of the paw that I can send separately.

Canine

RADIOGRAPHIC STUDY OF THE FRONT PAWS

BREED Mediolateral, Dorsopalmar and oblique views of the left front paw as well as Dorsopalmar of the right front paw provided for review, totaling 4 images.

Dachshund x Chihuahua

RADIOGRAPHIC FINDINGS

SEX The distal left front limb is split between the radius and the ulna. The 2nd digit is attached to the radius and radiocarpal bone with a complete set of metacarpal bone as well as proximal middle and distal phalanx. The first digit and 3rd-5th digit are attached to the ulnocarpal bone, accessory carpal bone, and 3rd and 4th carpal bones. Malalignment of the phalanges and claw horns as well as toe pads is noted. The ulna appears to be significantly shorter than the radius.

Male

AGE The right front paw presents within age related normal limits.

14 Weeks **RADIOGRAPHIC DIAGNOSIS**

- Ectrodactyly of the left front paw

INTERPRETED BY

Nele Eley (Ondreka),
 DVM Dr. med. vet.,
 DipECVDI

INTERPRETATION OF FINDINGS & FURTHER RECOMMENDATIONS

The radiographic study shows a congenital malformation of the front paw with split between the radius and 2nd digit from the ulna and the remainder of the digits. Therapeutic goals could be to surgically reconstruct a walkable paw pad. If that is not an option, an orthosis could be considered before considering final solutions such as amputation. Amputation of the 2nd digit could be one solution based on the radiographic presentation. However clinical correlation is required.

HOSPITAL NAME

Gentle Doc AH

REFERRING VET

Dr. Taylor Morrison

INVOICE

29767

DATE

11/11/21



PATIENT

Sammy Reynolds

SPECIES

Canine

BREED

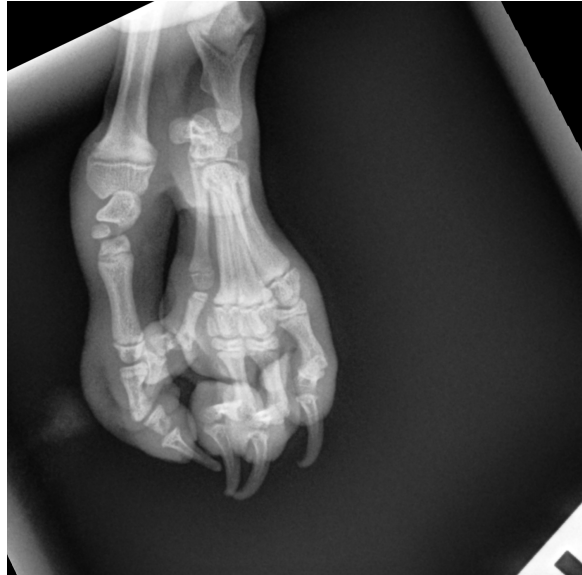
Dachshund x
Chihuahua

SEX

Male

AGE

14 Weeks



The information and recommendations provided are based on the images presented by the referring veterinarian. No evaluation can be communicated regarding pathology that was not visible in the image/video clips provided.

Thank you for this referral. If the clinical or image interpretation does not parallel your findings or if I can be of any further assistance please contact me.

INTERPRETED BY

Nele Eley (Ondreka),
DVM Dr. med. vet.,
DipECVDI

Nele Eley (Ondreka), DVM, Dr. med. vet., DipECVDI
European Specialist in Veterinary Diagnostic Imaging, Cert. Radiology,
Senior lecturer University of Giessen/Germany, Veterinary Faculty, Department of Radiology.
Nele.Eley@sonopath.com

HOSPITAL NAME

Gentle Doc AH

REFERRING VET

Dr. Taylor Morrison

INVOICE

29767

DATE

11/11/21