

PATIENT PRESENTING CLINICAL SIGNS

Lilo Karpinski Coughing sneezing rattles/gurgle 3-4 times a day brother from litter had lung cancer
Abnormal PE/Chem/CBC/UA Results: No murmur or arrhythmia. INCREASED LUNG SOUNDS,
WHEEZING

SPECIES RADIOGRAPHIC STUDY OF THE THORAX

Feline Right/left lateral and ventrodorsal views totaling 6 images provided for review.

BREED RADIOGRAPHIC FINDINGS

Pixie Bob X The lungs are deeply inflated. The rib cage is expanded. A moderate generalized bronchial lung pattern is seen with marked peribronchial cuffing. There is lobar atelectasis of the left cranial and right middle lobes.

SEX Mild spondyloses are present within the mid and caudal thoracic spine. Course and width of the trachea are considered within normal limits. There is no radiographic evidence of cardiovascular pathology.
Spayed Female The mediastinum is within normal limits.

AGE RADIOGRAPHIC DIAGNOSIS

14 Years

- Active chronic lower airway pattern with air trapping and multilobar atelectasis

INTERPRETED BY INTERPRETATION OF FINDINGS & FURTHER RECOMMENDATIONS

Nele Eley (Ondreka), DVM Dr. med. vet., DipECVDI The radiographic findings are highly suggestive for recurrent allergic lower airway syndrome. The atelectasis of the left cranial and right middle lobes is likely due to mucus plugging of the lobar bronchi, and may well be irreversible. Theoretically, infectious bronchitis such as viral, bacterial, and less likely parasitic or protozoal is a potential differential diagnosis. Lower airway sampling would be ideal for further definition. However, an attempt of medical treatment for feline asthma could be considered as an alternative. There is no evidence of pulmonary masses or nodules.

HOSPITAL NAME

Elizabeth AH

REFERRING VET

Dr. Kim Allyn

INVOICE

29773

DATE

11/11/21



PATIENT

Lilo Karpinski

SPECIES

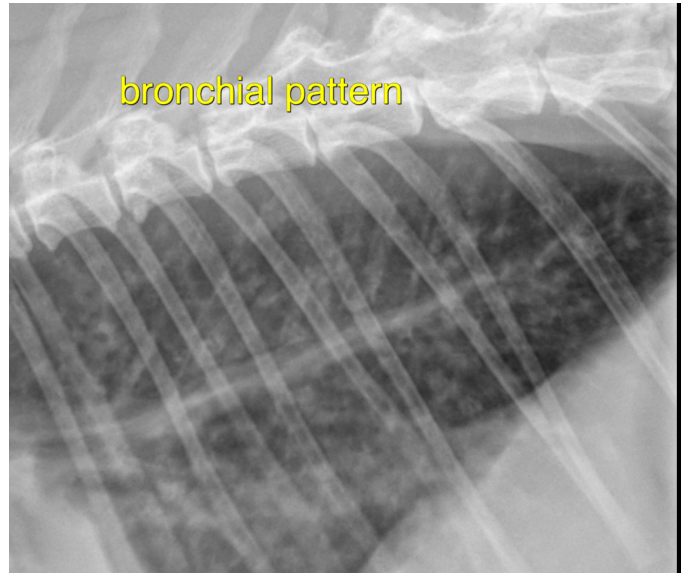
Feline

BREED

Pixie Bob X

SEX

Spayed Female



AGE

14 Years

The information and recommendations provided are based on the images presented by the referring veterinarian. No evaluation can be communicated regarding pathology that was not visible in the image/video clips provided.

Thank you for this referral. If the clinical or image interpretation does not parallel your findings or if I can be of any further assistance please contact me.

INTERPRETED BY

Nele Eley (Ondreka),
DVM Dr. med. vet.,
DipECVDI

Nele Eley (Ondreka), DVM, Dr. med. vet., DipECVDI
European Specialist in Veterinary Diagnostic Imaging, Cert. Radiology,
Senior lecturer University of Giessen/Germany, Veterinary Faculty, Department of Radiology.
Nele.Eley@sonopath.com

HOSPITAL NAME

Elizabeth AH

REFERRING VET

Dr. Kim Allyn

INVOICE

29773

DATE

11/11/21