



PATIENT

Pierre Paquette

SPECIES

Canine

BREED

Great Pyreneese Mix

SEX

MN

AGE

7Y, 3M

WEIGHT

66.45kg

INTERPRETED BY

Nele Eley (Ondreka),
DVM Dr. med. vet.,
DipECVDI

IMAGING PERFORMED BY

Dr Brian Barnes

HOSPITAL NAME

Westview Veterinary
Hospital

REFERRING VET

Dr Brian Barnes

INVOICE

72542

DATE

11-10-25

PRESENTING CLINICAL SIGNS

Kistory limping non weight bearing LH leg

Abnormal PE/Chem/CBC/UA Results: Full tear of the CCL, Positive CTT and Cranial drawer,
Minamal Medial buttress

ULTRASONOGRAPHIC FINDINGS

Left Stifle

The cranial cruciate ligament presents as a stump of echogenic fibers at the intercondylar eminence of the tibia and appears to be fully discontinuous. Surrounding hypoechoic halo is seen.

Both the lateral and medial meniscus demonstrate normal triangular contour, echogenicity, and smooth margins. No evidence of prolapse or meniscal tearing is seen.

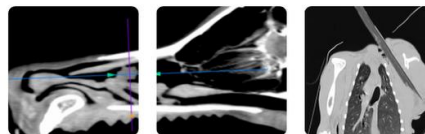
Moderate thickening of the synovium and moderate anechoic effusion is seen. There is mild periarticular osteophytosis.

ULTRASONOGRAPHIC DIAGNOSIS

- Complete rupture of the left cranial cruciate ligament
- Mild to moderate osteoarthritis of the left stifle joint.
- Normal ultrasonographic presentation of the medial and lateral menisci.

INTERPRETATION OF FINDINGS & FURTHER RECOMMENDATIONS

The ultrasonographic findings confirm a complete tear of the left cranial cruciate ligament with concomitant moderate osteoarthritic remodeling and effusion. The menisci remain structurally intact at this time and there is no ultrasonographic evidence of meniscal tearing. Perpetual biomechanical instability of the stifle joint, however, poses a risk for medial meniscal injury. Orthopedic stabilization such as by TPLO or TTA, or a comparable technique is indicated given the full rupture.



PATIENT

Pierre Paquette

SPECIES

Canine

BREED

Great Pyreneese Mix

SEX

MN

AGE

7Y, 3M

WEIGHT

66.45kg

INTERPRETED BY

Nele Eley (Ondreka),
DVM Dr. med. vet.,
DipECVDI

IMAGING PERFORMED BY

Dr Brian Barnes

HOSPITAL NAME

Westview Veterinary
Hospital

REFERRING VET

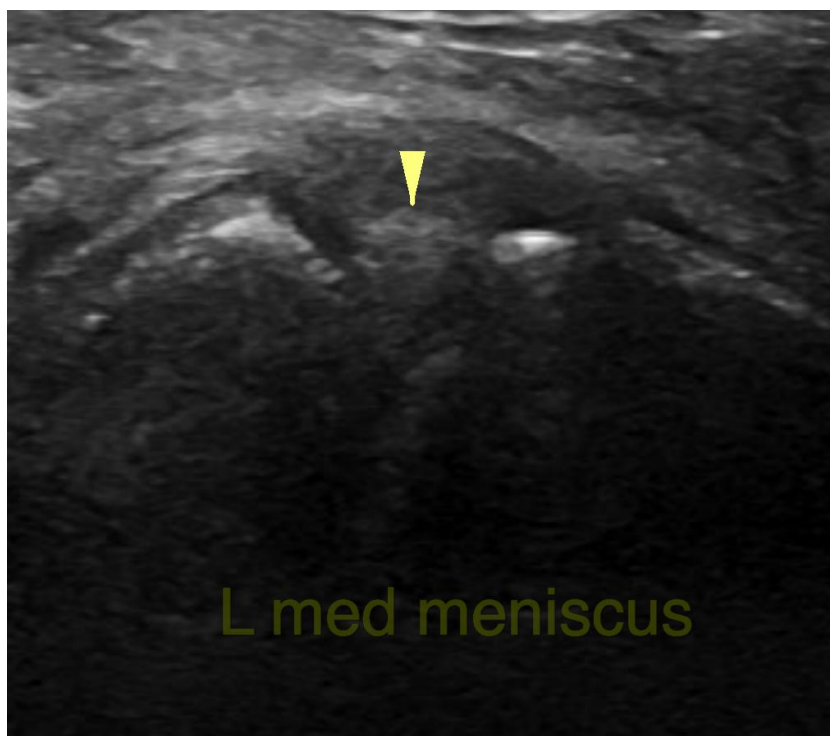
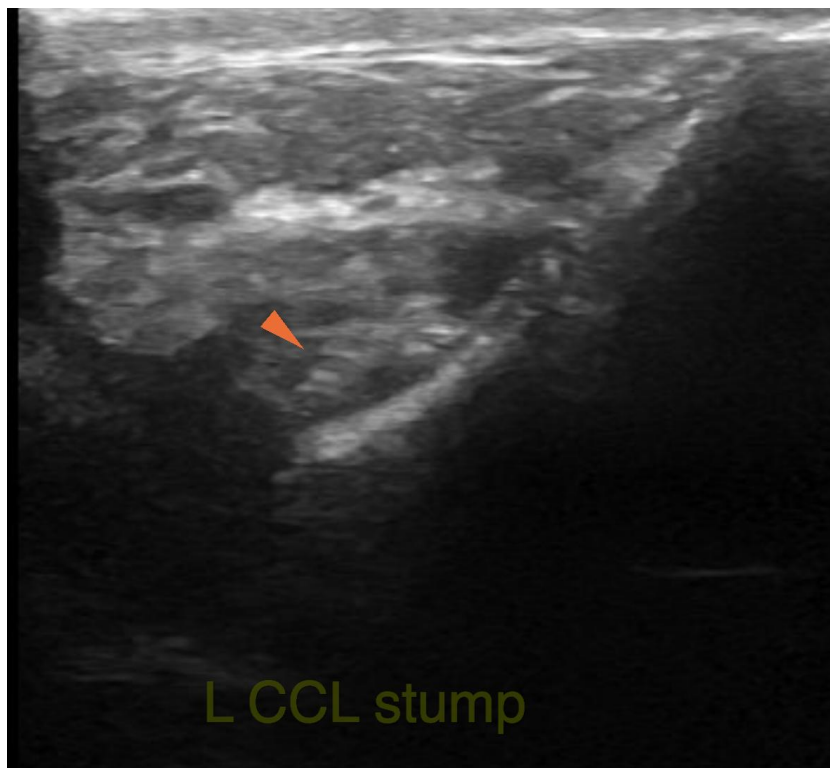
Dr Brian Barnes

INVOICE

72542

DATE

11-10-25





PATIENT

Pierre Paquette

SPECIES

Canine

BREED

Great Pyreneese Mix

SEX

MN

AGE

7Y, 3M

WEIGHT

66.45kg

INTERPRETED BY

Nele Eley (Ondreka),
DVM Dr. med. vet.,
DipECVDI

IMAGING PERFORMED BY

Dr Brian Barnes

HOSPITAL NAME

Westview Veterinary
Hospital

REFERRING VET

Dr Brian Barnes

INVOICE

72542

DATE

11-10-25

The information and recommendations provided are based on the images presented by the referring veterinarian. No evaluation can be communicated regarding pathology that was not visible in the image/video clips provided.

Thank you for this referral. If the clinical or image interpretation does not parallel your findings or if I can be of any further assistance please contact me.

Nele Eley (Ondreka), DVM, Dr. med. vet., DipECVDI

European Specialist in Veterinary Diagnostic Imaging, Cert. Radiology,
Senior lecturer University of Giessen/Germany, Veterinary Faculty, Department of Radiology.
info@sonopath.com