

PATIENT

Lexie Saunders

SPECIES

Canine

BREED

Golden Doodle

SEX

Female Spayed

AGE

5

WEIGHT

31.5kg

INTERPRETED BY

Nele Eley (Ondreka),
DVM Dr. med. vet.,
DipECVDI

IMAGING PERFORMED BY

RVT

HOSPITAL NAME

Oxford County
Veterinary Clinic

REFERRING VET

Emilie Dewes

INVOICE

72553

DATE

11-10-25

PRESENTING CLINICAL SIGNS

Front limb lameness ongoing for 2-3 months which has not worsened and only mildly improves with rest. Lameness is exacerbated by exercise. No obvious trauma but Lexie does infrequently jump off of furniture. Lately she has been getting off of the couch/bench in the home gingerly but does occasionally jump off when excited. As of late there is no off leash activity. No obvious trauma or injuries. LH CCL repaired by TPLO in 2023. Current medications are daily Metacam and Apoquel. She has had 2 doses of Topical Bravecto dispensed in 2025, last dose was given in October. No ticks have been found. 4dx negative today (November 10 2025). Grass awn was removed from an interdigital cyst in the RF paw pad in January 2025. Concurrent conditions - atopy and food allergies Pancreatitis in September 2025

Abnormal PE/Chem/CBC/UA Results: - Gait: At walk there is mild lameness on RF, head bob when weight bearing on RF. LF limb rotates medially when weight bearing. No ataxia or scuffing - RF: Crepitus on RF carpus, mildly dropped/ hyper-extended at carpus at a stand. No appreciable discomfort. Normal ROM on all joints. No edema or swelling of joints. - LF: No crepitus, no edema or swelling of joints, normal ROM on all joints - Dorsum: Mild sensitivity to spinal palpation - LH: Mild thickening of stifle (CCL rupture that was repaired with TPLO). Mild stiffness for flexion of stifle. Otherwise normal - RH: Normal ROM, no edema/swelling of joints, no crepitus

RADIOGRAPHIC STUDY OF THE SHOULDERS, ELBOWS, & CARPI

Mediolateral and craniocaudal views of shoulders, elbows, and carpi totaling 8 images available for review.

RADIOGRAPHIC FINDINGS

Shoulders

The bones are normal in density and congruity. No evidence of osteophyte formation, subchondral bone defects, subchondral sclerosis, or mineralized bodies within the joint space are seen.

The bicipital groove and greater tubercle margins are smooth and intact.

No soft tissue swelling or mineralization of periarticular structures are identified.

Elbows

The joint surfaces are normal in alignment; joint congruity is maintained. There is no evidence of opacity or contour changes of the medial coronoid process. No evidence of subchondral bone defects within the humeral condyle is seen. There is no evidence of significant osteophyte formation or subtrochlear notch sclerosis of the ulna.

Carpi

Carpal alignment is normal with no luxation or subluxation. The joint margins are smooth and distinct. No radiographic evidence of degenerative joint disease or periarticular mineralization is seen. Bone cortices and medullary cavities appear within normal limits. There is no abnormal soft tissue swelling noted.

The front paws present normal osseous structure and alignment.

Interphalangeal joints and metacarpophalangeal articulations are within age related normal limits.



PATIENT

Lexie Saunders

SPECIES

Canine

BREED

Golden Doodle

SEX

Female Spayed

AGE

5

WEIGHT

31.5kg

INTERPRETED BY

Nele Eley (Ondreka),
DVM Dr. med. vet.,
DipECVDI

IMAGING PERFORMED BY

RVT

HOSPITAL NAME

Oxford County
Veterinary Clinic

REFERRING VET

Emilie Dewes

INVOICE

72553

DATE

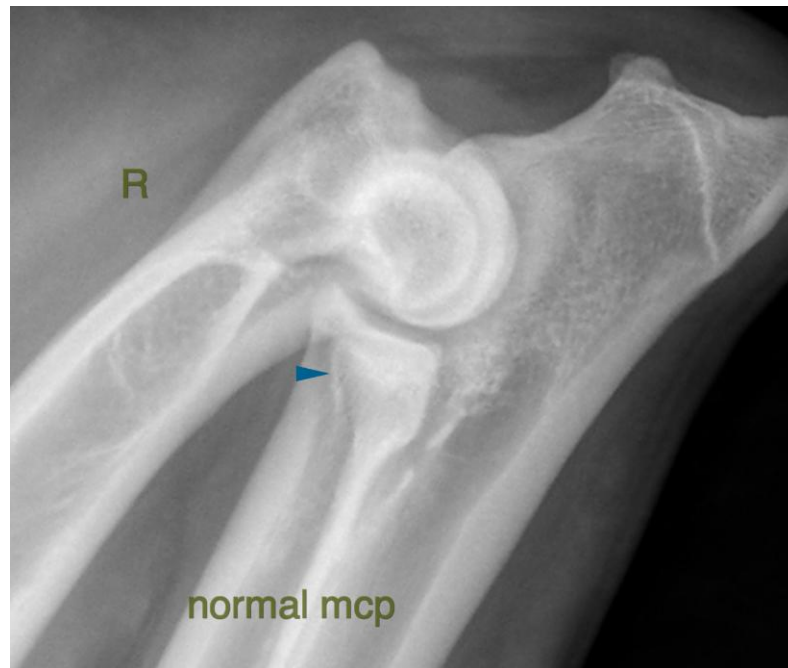
11-10-25

RADIOGRAPHIC DIAGNOSIS

- Normal radiographic presentation of both thoracic limbs including shoulders, elbows, carpi, and front paws.

INTERPRETATION OF FINDINGS & FURTHER RECOMMENDATIONS

There is no radiographic evidence of osseous, articular, or soft tissue pathology to explain the reported lameness in the radiographic study of the shoulders, elbows, and carpi. The absence of radiographic abnormality suggests a non-osseous or soft tissue related cause of the forelimb lameness such as musculotendinopathy or neurologic disease. Further definition may require cross-sectional imaging such as MRI or CT depending on the clinical correlation. Orthopedic reevaluation may be considered. Diagnostic anesthesia of the carpal and shoulder regions could be considered as well.



The information and recommendations provided are based on the images presented by the referring veterinarian. No evaluation can be communicated regarding pathology that was not visible in the image/video clips provided.

Thank you for this referral. If the clinical or image interpretation does not parallel your findings or if I can be of any further assistance please contact me.

Nele Eley (Ondreka), DVM, Dr. med. vet., DipECVDI

European Specialist in Veterinary Diagnostic Imaging, Cert. Radiology,
Senior lecturer University of Giessen/Germany, Veterinary Faculty, Department of Radiology.
info@sonopath.com