



PATIENT

Ginny Mencil

SPECIES

Canine

BREED

Beagle

SEX

Intact Female

AGE

11W

WEIGHT

10.12lbs

INTERPRETED BY

Nele Eley (Ondreka),
DVM Dr. med. vet.,
DipECVDI

IMAGING PERFORMED BY

JL/MF

HOSPITAL NAME

The Pet Hospital of
Stratford

REFERRING VET

Dr. Claudia Giuliani,
DVM

INVOICE

72582

DATE

11-11-25

PRESENTING CLINICAL SIGNS

Recheck thorax rads

RADIOGRAPHIC STUDY OF THE THORAX

Right/left lateral and ventrodorsal views of the thorax totaling 3 images available for review.

RADIOGRAPHIC FINDINGS

The pulmonary inflation is deep. There is a moderate patchy alveolar pattern most prominent in the cranioventral lung fields and slightly more accentuated on the left side. Generalized bronchial wall thickening with peribronchial cuffing is seen consistent with concomitant bronchial and peribronchial inflammation.

The cardiac silhouette presents within normal limits. The VHS is approximately 10 and within normal limits for a puppy of this size.

The trachea is normal in position and diameter.

A normal thymic remnant is present in the cranioventral mediastinum.

No evidence of pleural effusion is noted.

The abdominal serosal detail is still reduced which is normal for a puppy of this age.

RADIOGRAPHIC DIAGNOSIS

- Moderate cranioventrally accentuated alveolar infiltrate with generalized bronchial pattern.
- Normal trachea and normal cardiac silhouette.

INTERPRETATION OF FINDINGS & FURTHER RECOMMENDATIONS

The radiographic findings are compatible with resolving or persistent bronchopneumonia. The combination of a patchy cranioventral alveolar pattern with generalized bronchial thickening and cuffing is most consistent with bronchopneumonia, which in this age group is most commonly infectious and may be secondary to bacterial/viral respiratory disease. Aspiration is a less likely differential diagnosis. Continued clinical monitoring and follow up imaging are recommended to ensure resolution. Note that the resolution of imaging changes may lag behind the clinical improvement.



PATIENT

Ginny Mencil

SPECIES

Canine

BREED

Beagle

SEX

Intact Female

AGE

11W

WEIGHT

10.12lbs

INTERPRETED BY

Nele Eley (Ondreka),
DVM Dr. med. vet.,
DipECVDI

IMAGING PERFORMED BY

JL/MF

HOSPITAL NAME

The Pet Hospital of
Stratford

REFERRING VET

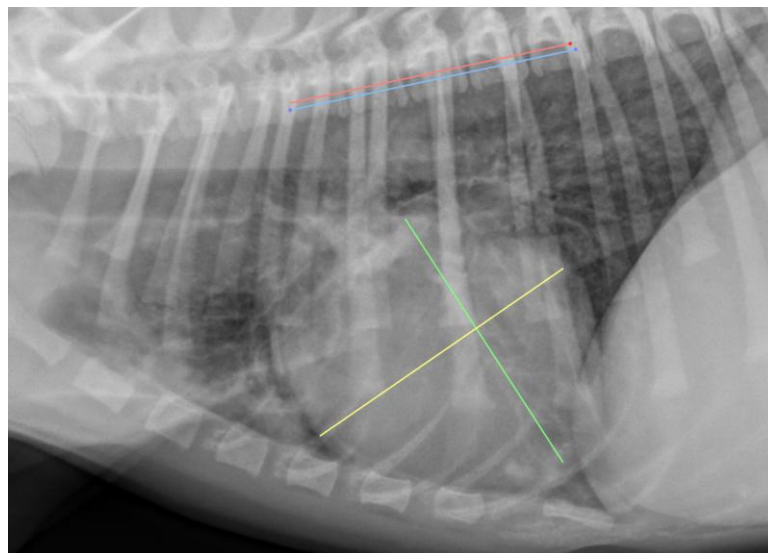
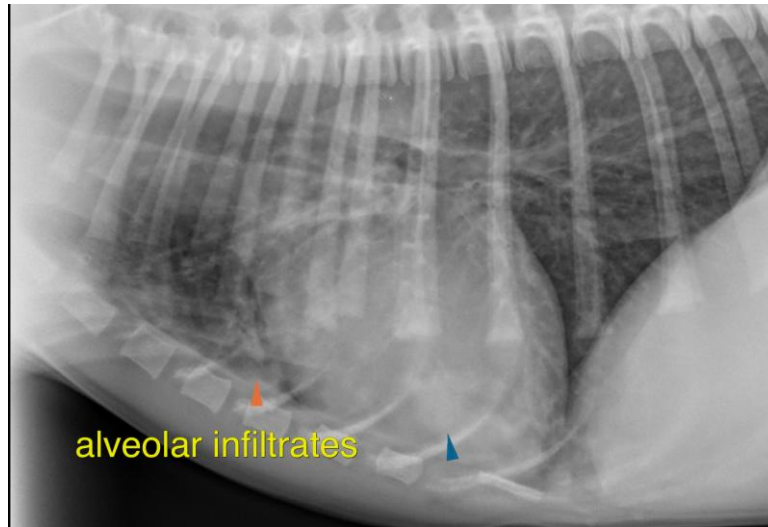
Dr. Claudia Giuliani,
DVM

INVOICE

72582

DATE

11-11-25



The information and recommendations provided are based on the images presented by the referring veterinarian. No evaluation can be communicated regarding pathology that was not visible in the image/video clips provided.

Thank you for this referral. If the clinical or image interpretation does not parallel your findings or if I can be of any further assistance please contact me.

Nele Eley (Ondreka), DVM, Dr. med. vet., DipECVDI

European Specialist in Veterinary Diagnostic Imaging, Cert. Radiology,

Senior lecturer University of Giessen/Germany, Veterinary Faculty, Department of Radiology.

info@sonopath.com