



PATIENT

Sam Brown

SPECIES

Fel

BREED

DLH

SEX

MN

AGE

10

INTERPRETED BY

Nele Eley, DVM
Dr. med. Vet. DipECVDI

HOSPITAL NAME

Golden Isles Animal
Hospital

REFERRING VET

James Hornbuckle

INVOICE

55107

DATE

11-10-22

PRESENTING CLINICAL SIGNS

Px had full mouth extraction on tuesday for severe dental dz. Procedure was without complication and px vitals during procedure were wnl, save for some late hypothermia. Px presented 11-10-2022 for supportive care as he was inappetent and appeared to be in discomfort. Upon presentation open mouth breathing was noted and chest xrays were taken to explore further

Abnormal PE/Chem/CBC/UA Results: Pre surgical labs were wnl

RADIOGRAPHIC STUDY OF THE THORAX

Right/left lateral and ventrodorsal views of the thorax totaling 3 images available for review.

RADIOGRAPHIC FINDINGS

The ribcage is expanded. The lungs are deeply inflated.

There is an asymmetrically distributed severe cranioventral alveolar infiltrate involving the right and left lung. Compensatory overinflation of the caudodorsal lung is seen. Deep inhalation is also indicated by a relatively wide trachea.

Assessment of the cardiac silhouette is obscured however there is no evidence of cardiomegaly, atrial enlargement, vascular lung pattern, or pleural effusion.

No evidence of mediastinal involvement is noted.

Moderate gastric aerophagia is noted.

RADIOGRAPHIC DIAGNOSIS

- Severe cranioventral alveolar pulmonary infiltrate.
- Aerophagia.
- Compensatory hyperinflation as a consequence of respiratory distress.

INTERPRETATION OF THE FINDINGS & FURTHER RECOMMENDATIONS

The radiographic findings are suggestive for pneumonia. Aspiration pneumonia is considered most likely. Infectious pneumonia cannot be ruled out entirely as a differential diagnosis even though considered by far less likely. Other low potentials would include acute respiratory distress syndrome however at this point, aspiration pneumonia should be considered a primary differential diagnosis. Further treatment for pneumonia is strongly recommended.



PATIENT

Sam Brown

SPECIES

Fel

BREED

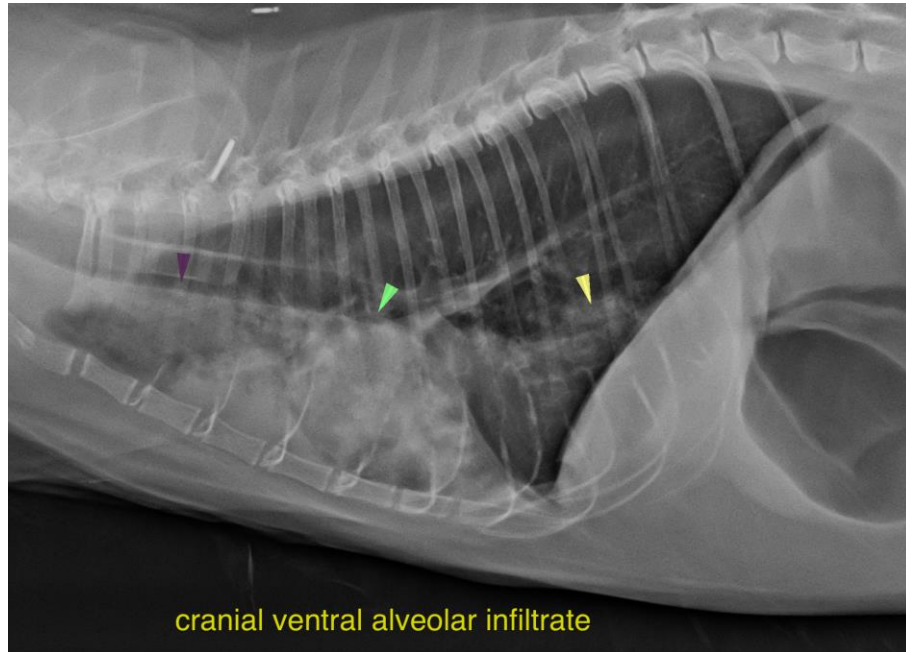
DLH

SEX

MN

AGE

10



INTERPRETED BY

Nele Eley, DVM
Dr. med. Vet. DipECVDI

The information and recommendations provided are based on the images presented by the referring veterinarian/sonographer. No evaluation can be communicated regarding pathology that was not visible in the image/video clips provided.

Thank you for this referral. If the clinical or image interpretation does not parallel your findings or if I can be of any further assistance please contact me.

HOSPITAL NAME

Golden Isles Animal
Hospital

Nele Eley, DVM, Dr. med. vet., DipECVDI
European Specialist in Veterinary Diagnostic Imaging, Cert. Radiology,
Senior lecturer University of Giessen, Germany, Veterinary Faculty, Department of Radiology
Nele.Eley@sonopath.com

REFERRING VET

James Hornbuckle

INVOICE

55107

DATE

11-10-22