



PATIENT

Monroe Galfano

PRESENTING CLINICAL SIGNS

Vomits every other day x 3 months
Abnormal PE/Chem/CBC/UA Results: palpably thickened intestines and hair loss over abdomen
CBC/ CHEM/ UA nl

SPECIES

Feline

RADIOGRAPHIC STUDY OF THE THORAX & ABDOMEN

Right/left lateral and ventrodorsal whole body views totaling 3 images available for review.

BREED

DSG

RADIOGRAPHIC FINDINGS

Abdomen

The surrounding bony structures are within normal limits.

SEX

MN

No abnormalities of the extraabdominal soft tissues are noted. The abdominal wall is smooth and thin.

The serosal detail is maintained throughout the peritoneal and retroperitoneal space.

AGE

8 Years

The liver is appropriate in position, size and presents uniform opacity.

The splenic head is in the anticipated position and within normal limits for size and opacity. The splenic tail is not seen.

INTERPRETED BY

Nele Eley, DVM
Dr. med. Vet. DipECVDI

Both kidneys are seen and present with normal size, shape, delineation and opacity. The urinary bladder is in its anticipated position. No radiopaque calculi are noted throughout the upper and lower urinary tract.

HOSPITAL NAME

Northshore
Veterinary Hospital

The stomach is in its anticipated position and presents normal content.

There appears to be diffuse thickening of the small intestinal loops subjectively.

The colon is seen in the expected position and presents with appropriate content.

REFERRING VET

Brita Kiffney

Thorax

The surrounding bony structures are within normal limits.

The extrathoracic soft tissues present homogeneous without abnormalities.

INVOICE

55112

The heart is of normal size and shape and there is no evidence of cardiac chamber or vascular enlargement. The pulmonary vasculature is within normal limits.

The cranial mediastinum presents the expected soft tissue opacity. The mediastinal width is less than twice the width of the vertebral column at the same level.

DATE

11-10-22

The trachea is normal in diameter and presents the anticipated course. The luminal outline of the trachea is smooth.



PATIENT

The degree of pulmonary inflation is deep. A mild generalized bronchial lung pattern is noted.

Monroe Galfano

The diaphragm is well delineated with even surface and the expected mild cranial bulging of the diaphragmatic cupola.

SPECIES

Feline

RADIOGRAPHIC DIAGNOSIS

- Suspect diffuse small intestinal wall thickening.
- Mild bronchial lung pattern.

BREED

DSG

INTERPRETATION OF THE FINDINGS & FURTHER RECOMMENDATIONS

The radiographic findings further support the presence of diffuse small intestinal wall thickening which may be due to infiltrative disease such as round cell neoplasia or inflammatory bowel disease. The diagnostic accuracy of radiographs however is limited in terms of architectural wall changes and potential concurrent lymph node changes. Further definition by means of full abdominal ultrasound with eventual sampling could be considered if not performed already.

SEX

MN

The bronchial lung pattern may be within age related normal limits. Lower airway disease such as eosinophilic bronchopneumopathy or infectious bronchitis is a potential differential diagnosis which may be clinically silent at this point.

AGE

8 Years

INTERPRETED BY

Nele Eley, DVM
Dr. med. Vet. DipECVDI

HOSPITAL NAME

Northshore
Veterinary Hospital

REFERRING VET

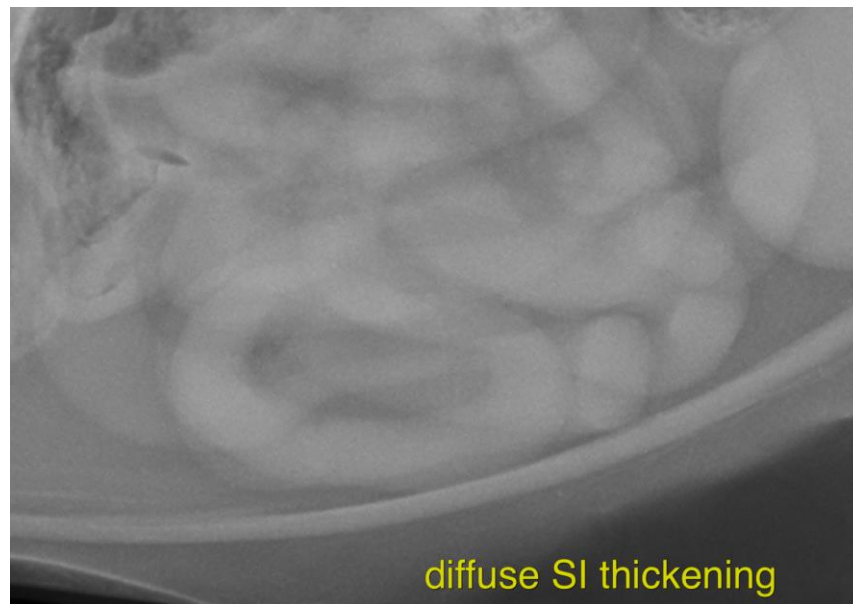
Brita Kiffney

INVOICE

55112

DATE

11-10-22





PATIENT

Monroe Galfano

The information and recommendations provided are based on the images presented by the referring veterinarian/sonographer. No evaluation can be communicated regarding pathology that was not visible in the image/video clips provided.

Thank you for this referral. If the clinical or image interpretation does not parallel your findings or if I can be of any further assistance please contact me.

SPECIES

Feline

Nele Eley, DVM, Dr. med. vet., DipECVDI
European Specialist in Veterinary Diagnostic Imaging, Cert. Radiology,
Senior lecturer University of Giessen, Germany, Veterinary Faculty, Department of Radiology
Nele.Eley@sonopath.com

BREED

DSG

SEX

MN

AGE

8 Years

INTERPRETED BY

Nele Eley, DVM
Dr. med. Vet. DipECVDI

HOSPITAL NAME

Northshore
Veterinary Hospital

REFERRING VET

Brita Kiffney

INVOICE

55112

DATE

11-10-22