



PATIENT PRESENTING CLINICAL SIGNS

Shelly Naasz Shelly is an 11 y/o FS DSH that has chronic nasal congestion and nasal discharge primarily unilateral for the past year and a half. Shelly is on Azithromycin and has been receiving Depomedrol injections on a monthly basis to help manage congestion and intermittent inappetance.

SPECIES Abnormal PE/Chem/CBC/UA Results: High fPLI - 6.0 (0-3.5) Mild Neutrophilia Hematuria (2+)

Feline

COMPUTED TOMOGRAPHIC STUDY OF THE HEAD

BREED Plain and post contrast studies available for review.

DSH COMPUTED TOMOGRAPHIC FINDINGS

SEX The brain presents no deviation from normal anatomy and symmetry. The grey and white matter distinction and the neuroparenchymal attenuation are as expected. The distribution of contrast enhancement is within normal limits throughout the parenchyma and meninges. The ventricular system is non-dilated and within the limits of the expected volume and symmetry.

Female

AGE Extensive fluid accumulation and mucosal swelling is seen within both nasal cavities. There is moderate multifocal turbinate destruction within both nasal cavities. Distortion of the osseous nasal septum with mild leftward deviation is noted. There is multifocal thinning and porosity of the nasal, palatinal, and maxillary bones. Hyperostosis of the frontal sinuses is seen accentuating the right side. Both frontal sinuses contain fluid attenuating material and present swelling of their mucosal lining. The right presphenoidal sinus and nasal fundus are filled with fluid attenuating material.

11 Years

INTERPRETED BY Both temporomandibular joints present congruent joint spaces with even subchondral bone surfaces and are considered within normal limits.

Nele Eley, DVM
Dr. med. Vet. DipECVDI

HOSPITAL NAME The left tympanic bulla is filled with fluid attenuating material. Mild thickening of the osseous lining of the tympanic bulla is seen. The external auditory meatuses present within normal limits.

Stephanie Salinas Both medial retropharyngeal and submandibular lymph nodes present mild symmetric enlargement with maintained short to long axis ratios and contrast enhancement patterns.

REFERRING VET The salivary glands present within normal limits.

Dr. Williams The dentition is incomplete. No dental changes associated with nasal pathology are seen; however, there are multiple resorptive lesions of the remaining teeth.

INVOICE COMPUTED TOMOGRAPHIC DIAGNOSIS

- 48286
- Moderate to severe bilateral chronic destructive rhinosinusitis.
 - Chronic left sided otitis media.
 - Mild bilateral medial retropharyngeal and submandibular lymphadenomegaly.

DATE INTERPRETATION OF THE FINDINGS & FURTHER RECOMMENDATIONS

11-10-21 The CT study reveals bilateral destructive rhinosinusitis with signs of chronicity. There also is left sided otitis media. Infectious rhinosinusitis and otitis such as chronic bacterial, fungal, or



PATIENT

Shelly Naasz

opportunistic infection is thought by far most likely. The changes are not typical for lymphoplasmacytic or allergic rhinitis. No evidence of a discrete soft tissue mass or foreign material is seen. Consider rhinoscopy with sampling for further definition if not performed already. Further otoscopic workup is recommended as well.

SPECIES

Feline

BREED

DSH

SEX

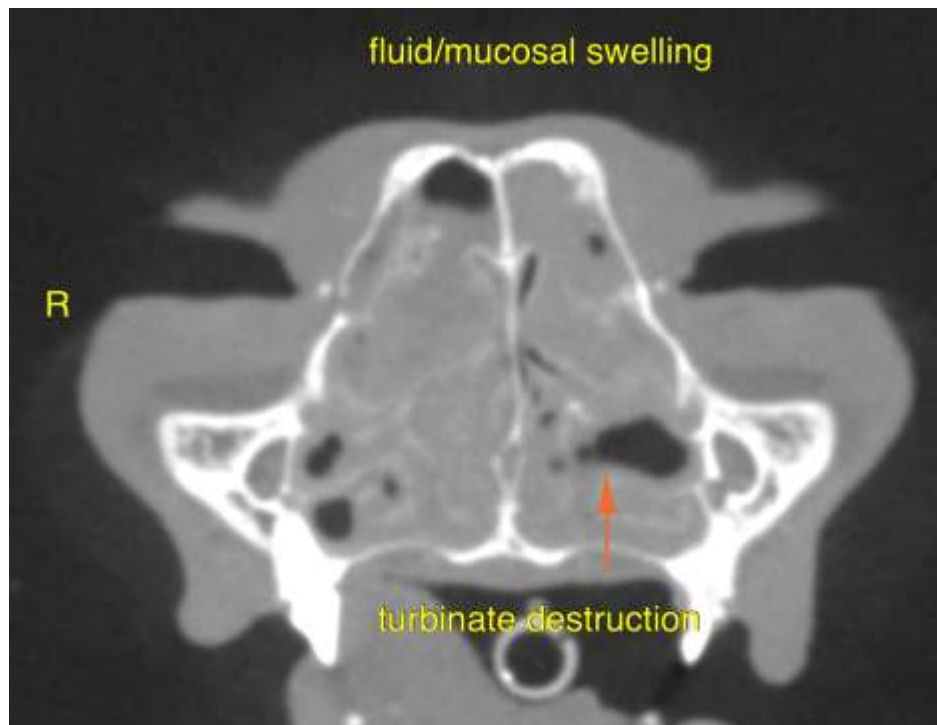
Female

AGE

11 Years

INTERPRETED BY

Nele Eley, DVM
Dr. med. Vet. DipECVDI



HOSPITAL NAME

Stephanie Salinas

REFERRING VET

Dr. Williams

The information and recommendations provided are based on the images presented by the referring veterinarian. No evaluation can be communicated regarding pathology that was not visible in the image/video clips provided.

Thank you for this referral. If the clinical or image interpretation does not parallel your findings or if I can be of any further assistance please contact me.

INVOICE

48286

Nele Eley, DVM, Dr. med. vet., DipECVDI
European Specialist in Veterinary Diagnostic Imaging, Cert. Radiology,
Senior lecturer University of Giessen, Germany, Veterinary Faculty, Department of Radiology
Nele.Eley@sonopath.com

DATE

11-10-21