



**PATIENT PRESENTING CLINICAL SIGNS**

Dusan Prole  
 Heart Sounds = \*\*\*\*grade 1/6 HM WHEN TACHYCARDIA HAPPENS, SINUS ARRHYTHMIA  
 Abnormal PE/Chem/CBC/UA Results: BW REVEALED VERY MILD ELEVATION OF BUN,  
 DUE TO DEHYDRATION HYPOCALCEMIA, CAN BE NUTRITIONAL WE CAN DO IONIZED CA  
 IF OWNER IS INTERESTED LOW WBC, CAN BE STRESS VS VIRAL, SINCE THE CAT IS  
 INDOOR, WILL RULE OUT VIRAL INFECTION

**SPECIES**

Feline

**RADIOGRAPHIC STUDY OF THE THORAX**

**BREED**

Right/left lateral and ventrodorsal views totaling 3 images available for review.

**DLH**

**RADIOGRAPHIC FINDINGS**

The surrounding bony structures are within normal limits.

**SEX**

The extrathoracic soft tissues present homogeneous without abnormalities.

Male Neutered

The heart is of normal size and shape and there is no evidence of cardiac chamber or vascular enlargement. The pulmonary vasculature is within normal limits. The vertebral heart score is 7.2.

**AGE**

10 Years

The cranial mediastinum presents the expected soft tissue opacity. The mediastinal width is less than twice the width of the vertebral column at the same level.

**INTERPRETED BY**

Nele Eley, DVM  
 Dr. med. Vet. DipECVDI

The trachea is normal in diameter and presents the anticipated course. The luminal outline of the trachea is smooth.

A mild generalized bronchial lung pattern with even distribution throughout all lung lobes is seen.

The diaphragm is well delineated with even surface and the expected mild cranial bulging of the diaphragmatic cupola.

**HOSPITAL NAME**

St. Catharine's Animal  
 Hospital

**RADIOGRAPHIC DIAGNOSIS**

- Radiographically normal thorax.

**REFERRING VET**

Dr. Boctor

**INTERPRETATION OF THE FINDINGS & FURTHER RECOMMENDATIONS**

The radiographic study reveals no structural evidence of cardiovascular pathology. The mild bronchial lung pattern is likely to represent a normal age related variant. However, underlying low grade lower airway disease cannot be ruled out entirely. Consider further definition only in case of pertinent clinical signs.

**INVOICE**

48284

**DATE**

11-10-21



**PATIENT**

Dusan Prole

**SPECIES**

Feline

**BREED**

DLH

**SEX**

Male Neutered

**AGE**

10 Years

**INTERPRETED BY**

Nele Eley, DVM  
Dr. med. Vet. DipECVDI

**HOSPITAL NAME**

St. Catharine's Animal  
Hospital

**REFERRING VET**

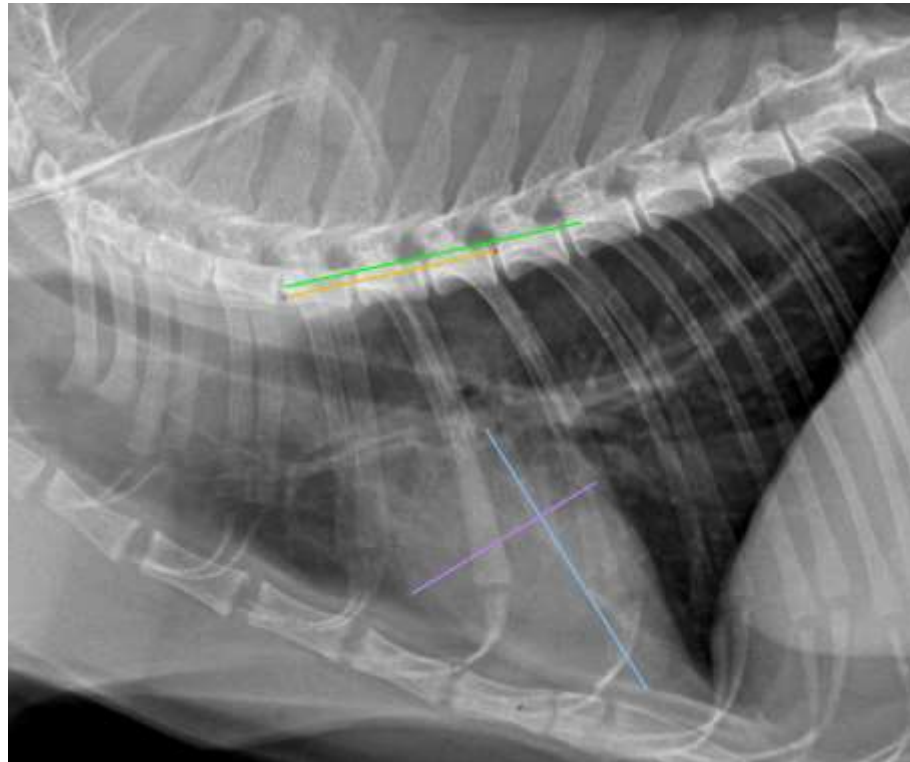
Dr. Boctor

**INVOICE**

48284

**DATE**

11-10-21



The information and recommendations provided are based on the images presented by the referring veterinarian. No evaluation can be communicated regarding pathology that was not visible in the image/video clips provided.

Thank you for this referral. If the clinical or image interpretation does not parallel your findings or if I can be of any further assistance please contact me.

**Nele Eley**, DVM, Dr. med. vet., DipECVDI  
European Specialist in Veterinary Diagnostic Imaging, Cert. Radiology,  
Senior lecturer University of Giessen, Germany, Veterinary Faculty, Department of Radiology  
Nele.Eley@sonopath.com