



PATIENT PRESENTING CLINICAL SIGNS

Pumpkin Smith Chronic congestion /coughing sneezing w/ blood droplets
Abnormal PE/Chem/CBC/UA Results: Severe gingivitis, missing teeth.

SPECIES COMPUTED TOMOGRAPHIC STUDY OF THE HEAD

Feline Plain and post contrast studies available for review.

COMPUTED TOMOGRAPHIC FINDINGS

BREED

DSH

Extensive bilateral nasal fluid accumulation and mucosal swelling is noted. The frontal sinuses contain a moderate amount of fluid attenuating material, left more than right, and present mucosal swelling as well. Mild hyperostosis of the external and internal laminae of the frontal sinuses is seen. There is moderate bilateral turbinate destruction. No evidence of aggressive bone lesions is found. The cribriform plate is intact. There is no evidence of nasopharyngeal stenosis.

SEX

Spayed Female

No tooth elements are present in the right maxillary dental arcade except for the triadans 101 and 102. 103 is absent in the left maxillary dental arcade as well as triadan 206. The triadans 207, 208, 209 present mild tooth root resorption. All incisor teeth of the left mandibular arcade are absent. Triadans 307 and 407 are absent as well.

AGE

8 Years

The submandibular lymph nodes present within normal limits.

Mild bilaterally symmetric retropharyngeal lymphadenomegaly is noted.

INTERPRETED BY COMPUTED TOMOGRAPHIC DIAGNOSIS

Nele Eley (Ondreka),
DVM Dr. med. vet.,
DipECVDI

- Moderate bilateral chronic erosive rhinosinusitis.
- Incomplete dentition with multiple absent teeth and ongoing dental root ankylosis accentuating the upper maxillary molar teeth.
- Bilateral mild medial retropharyngeal lymphadenomegaly.

HOSPITAL NAME INTERPRETATION OF FINDINGS & FURTHER RECOMMENDATIONS

Mobile Pet Imaging

The CT study reveals evidence of chronic bilateral erosive rhinosinusitis. Differential diagnosis includes chronic lymphoplasmacytic rhinitis, chronic viral or bacterial, and less likely chronic fungal rhinitis. Further definition by means of rhinoscopy with sampling could be considered if not performed already.

REFERRING VET

Meaux

The changes of the retropharyngeal lymph nodes are compatible with reactive hyperplasia.

INVOICE

54907

No direct indication for dental extractions can be drawn from the CT study. Correlation with the clinical dental workup recommended.

DATE

11-1-22



PATIENT

Pumpkin Smith

SPECIES

Feline

BREED

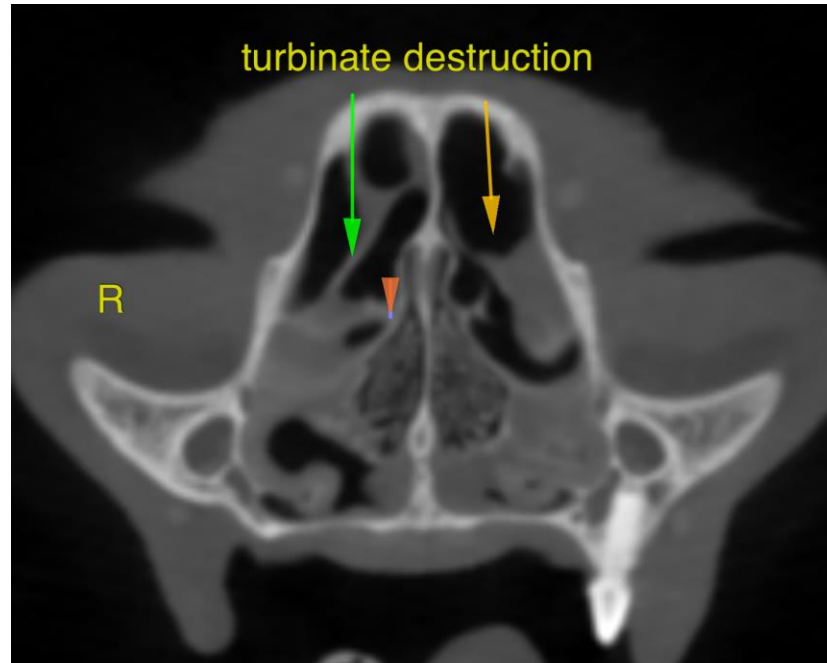
DSH

SEX

Spayed Female

AGE

8 Years



The information and recommendations provided are based on the images presented by the referring veterinarian. No evaluation can be communicated regarding pathology that was not visible in the image/video clips provided.

INTERPRETED BY

Nele Eley (Ondreka),
DVM Dr. med. vet.,
DipECVDI

Thank you for this referral. If the clinical or image interpretation does not parallel your findings or if I can be of any further assistance please contact me.

Nele Eley (Ondreka), DVM, Dr. med. vet., DipECVDI
European Specialist in Veterinary Diagnostic Imaging, Cert. Radiology,
Senior lecturer University of Giessen/Germany, Veterinary Faculty, Department of Radiology.
Nele.Eley@sonopath.com

HOSPITAL NAME

Mobile Pet Imaging

REFERRING VET

Meaux

INVOICE

54907

DATE

11-1-22