

**PATIENT**

Sylas Roy

PRESENTING CLINICAL SIGNS

PU/PD , distended abdomen
Abnormal PE/Chem/CBC/UA Results: elevated ALT, ALP Low t4

SPECIES

Canine

RADIOGRAPHIC STUDY OF THE ABDOMEN

Right/left lateral and ventrodorsal views totaling 3 images available for review.

BREED

Chihuahua Mix

RADIOGRAPHIC FINDINGS

The ventral abdominal wall is pendulous.

The abdominal serosal detail is maintained.

SEX

Male Neuter

The urinary bladder is severely distended but of uniform opacity.

The radiographic presentation of the kidneys and spleen is considered within normal limits.

Severe generalized enlargement of the liver with rounded lobar margins is seen.

AGE

8 Years

There is caudodorsal deviation of the gastric pylorus.

The descending duodenum is patent with a gas pattern; however, no evidence of abnormal dilation is seen.

INTERPRETED BY

Nele Eley, DVM
Dr. med. Vet. DipECVDI

RADIOGRAPHIC DIAGNOSIS

- Severe generalized hepatomegaly.
- Obesity.

HOSPITAL NAME

St. Catherine's Animal
Hospital

INTERPRETATION OF THE FINDINGS & FURTHER RECOMMENDATIONS

The radiographic findings are compatible with endocrine / metabolic hepatopathy. Diffuse inflammatory/infectious or neoplastic infiltrate of the liver cannot be ruled out as a differential diagnosis. Consider further laboratory workup with ultrasound and eventual parenchymal sampling if indicated.

REFERRING VET

Dr. Boctor

INVOICE

48162

DATE

11-1-21



PATIENT

Sylas Roy

SPECIES

Canine

BREED

Chihuahua Mix

SEX

Male Neuter

AGE

8 Years

INTERPRETED BY

Nele Eley, DVM
Dr. med. Vet. DipECVDI

HOSPITAL NAME

St. Catherine's Animal
Hospital

REFERRING VET

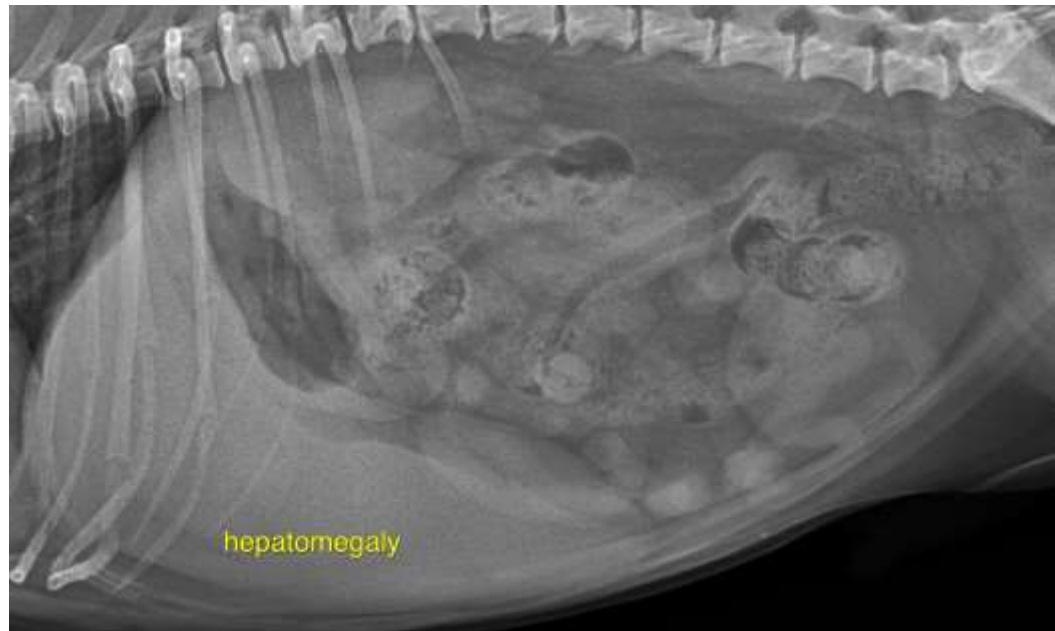
Dr. Boctor

INVOICE

48162

DATE

11-1-21



The information and recommendations provided are based on the images presented by the referring veterinarian. No evaluation can be communicated regarding pathology that was not visible in the image/video clips provided.

Thank you for this referral. If the clinical or image interpretation does not parallel your findings or if I can be of any further assistance please contact me.

Nele Eley, DVM, Dr. med. vet., DipECVDI
European Specialist in Veterinary Diagnostic Imaging, Cert. Radiology,
Senior lecturer University of Giessen, Germany, Veterinary Faculty, Department of Radiology
Nele.Eley@sonopath.com