SonoPath Teleradiology

EDUCATIONAL TELECONSULTATION SERVICES™

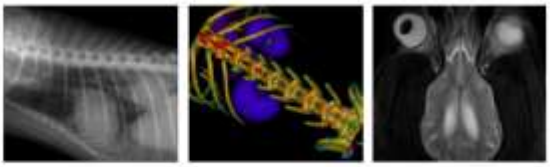

SonoPath.com
1-800-838-4268 info@sonopath.com

PATIENT

Daisy Peontek

SPECIES

Canine

BREED

Akbash

SEX

FS

AGE

8 Months

INTERPRETED BY

Nele Eley, DVM
Dr. med. Vet. DipECVDI

HOSPITAL NAME

Elizabeth Animal Hospital

REFERRING VET

Leon Anderson, DVM

INVOICE

48161

DATE

11-1-21

PRESENTING CLINICAL SIGNS

Intermittent lameness on left front and muscle loss. Rest of rads for orthopedic check.
Abnormal PE/Chem/CBC/UA Results: Muscle loss on left front shoulder

RADIOGRAPHIC STUDY OF THE ELBOWS, SHOULDERS, STIFLES, & PELVIS

Mediolateral views of both shoulders, mediolateral and craniocaudal views of both elbows, ventrodorsal hip extended view of the pelvis, and mediolateral and craniocaudal views of the stifles totaling 14 images available for review.

RADIOGRAPHIC FINDINGS

Shoulders

Regional subchondral lucency with deep peripheral sclerosis of the left humeral head are seen.

No evidence of a defect is seen in the right humeral head's subchondral bone.

Elbows

The medial coronoid process is evenly contoured and uniformly opacified in both elbows. There is no evidence of subchondral bone defects in the medial humeral condyles. The joint spaces are congruent. No evidence of osteoarthritis is noted.

Stifles

The subchondral bone of the distal femoral condyles is intact and smooth. No abnormal soft tissue swelling is seen. There is no evidence of traumatic osseous injury or early degenerative joint disease.

Pelvis

The left femoral head appears to be covered by the dorsal acetabular rim less so than the right one; however, this is mostly considered positional since there is mild leftward rotation of the pelvis.

The coxofemoral joint spaces are congruent and narrow. No evidence of osteoarthritis is seen.

The muscle volume of both hind limbs is adequate and symmetric.

RADIOGRAPHIC DIAGNOSIS

- Osteochondritis of the left humeral head.
- Radiographically normal right shoulder, elbows, stifles, and coxofemoral joints.

INTERPRETATION OF THE FINDINGS & FURTHER RECOMMENDATIONS

The radiographic study supports the presence of left humeral osteochondritis which appears to correlate well with the clinical findings. Arthroscopic revision of the shoulder could be considered.

SonoPath Teleradiology

EDUCATIONAL TELECONSULTATION SERVICES™

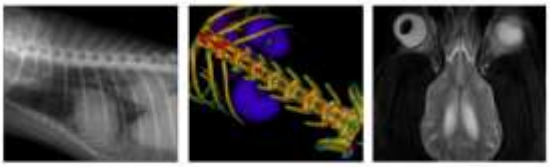

SonoPath.com
1-800-838-4268 info@sonopath.com

PATIENT

Daisy Peontek

SPECIES

Canine

BREED

Akbash

SEX

FS

AGE

8 Months

INTERPRETED BY

Nele Eley, DVM
Dr. med. Vet. DipECVDI

HOSPITAL NAME

Elizabeth Animal Hospital

REFERRING VET

Leon Anderson, DVM

INVOICE

48161

DATE

11-1-21

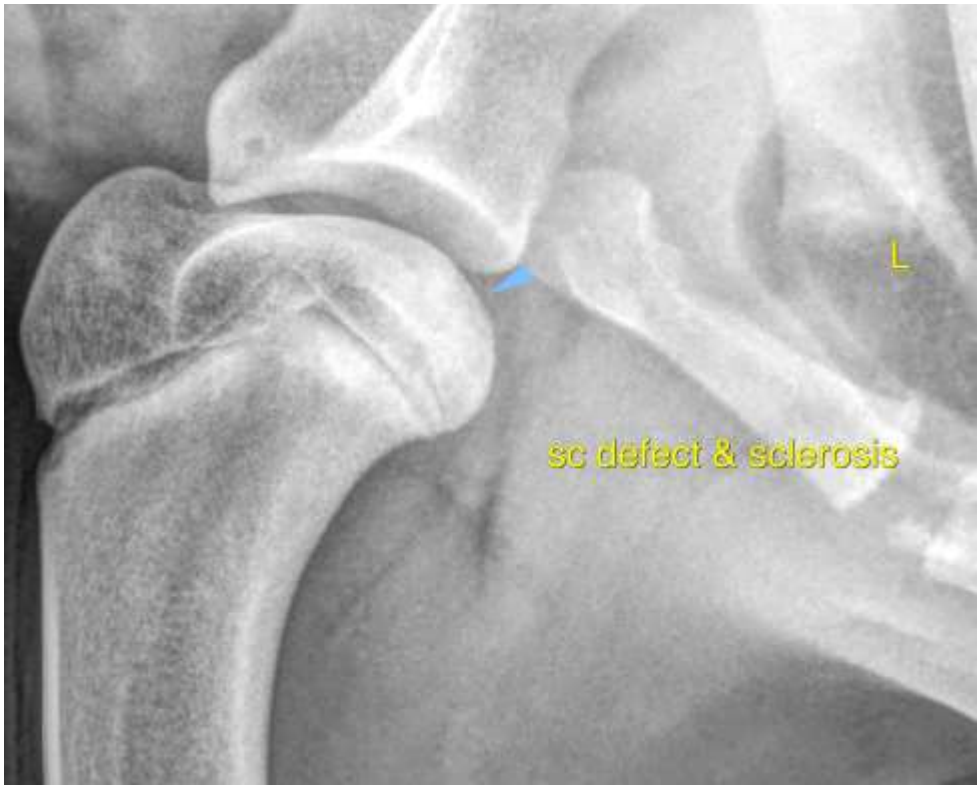

The information and recommendations provided are based on the images presented by the referring veterinarian. No evaluation can be communicated regarding pathology that was not visible in the image/video clips provided.

Thank you for this referral. If the clinical or image interpretation does not parallel your findings or if I can be of any further assistance please contact me.

Nele Eley, DVM, Dr. med. vet., DipECVDI
European Specialist in Veterinary Diagnostic Imaging, Cert. Radiology,
Senior lecturer University of Giessen, Germany, Veterinary Faculty, Department of Radiology
Nele.Eley@sonopath.com