



PATIENT

Eeyore Collins

PRESENTING CLINICAL SIGNS

Fluid filled swelling under mandible - suspect sialoceles vs other (infectious, neoplasia, cyst)

SPECIES

Canine

COMPUTED TOMOGRAPHIC STUDY OF THE HEAD & NECK

Plain and post contrast studies available for review.

BREED

Labrador Retriever
Mix

COMPUTED TOMOGRAPHIC FINDINGS

A thin walled cavitory lesion with uniformly fluid attenuating center and peripheral rim enhancement is seen in the sublingual position between the mandibles and in the upper neck. The lesion measures approximately 15 cm in length, 4 cm in width, and 2 cm in height. A tortuous and mildly dilated duct is seen which appears to connect to the sublingual salivary gland. A 5mm and 2mm long mineral attenuating structure is seen within the mildly dilated and tortuous duct respectively. No evidence of perilesional inflammation is seen.

SEX

Male

There is mild bilateral submandibular and retropharyngeal lymphadenomegaly.

AGE

9 Years

COMPUTED TOMOGRAPHIC DIAGNOSIS

- Sublingual sialoceles with sialolith formation
- Regional lymph node hyperplasia.

INTERPRETED BY

Nele Eley, DVM
Dr. med. Vet. DipECVDI

INTERPRETATION OF THE FINDINGS & FURTHER RECOMMENDATIONS

The CT findings are compatible with a large sublingual sialoceles. The dilated and tortuous duct is partially obstructed by at least 2 sialoliths and appears to connect to the left sublingual salivary gland. Other gland involvement however can never be ruled out entirely.

The lymph node changes are compatible with reactive hyperplasia.

HOSPITAL NAME

Scottsdale Veterinary
Clinic

REFERRING VET

Dr. Gans

INVOICE

54523

DATE

10-8-22



PATIENT

Eeyore Collins

SPECIES

Canine

BREED

Labrador Retriever
Mix

SEX

Male

AGE

9 Years

INTERPRETED BY

Nele Eley, DVM
Dr. med. Vet. DipECVDI

HOSPITAL NAME

Scottsdale Veterinary
Clinic

REFERRING VET

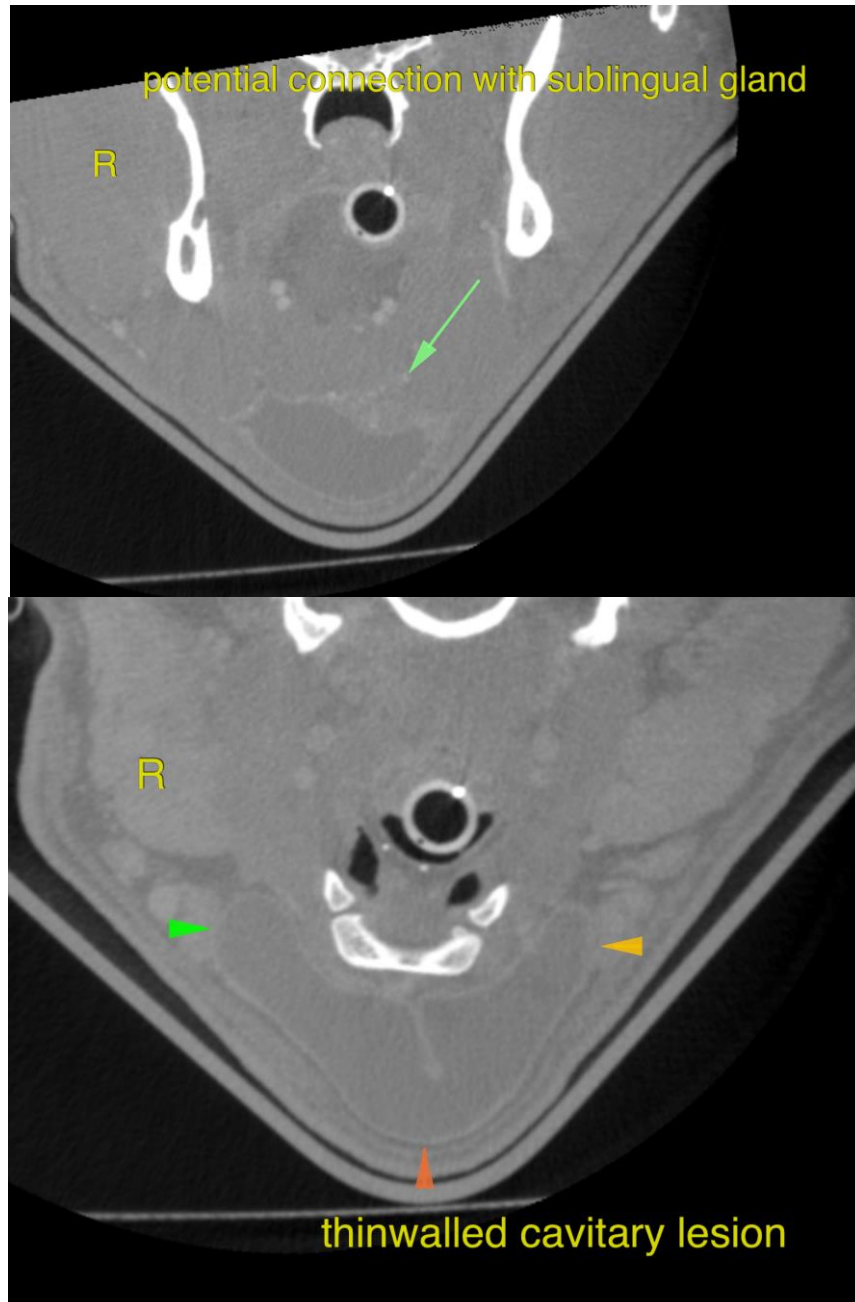
Dr. Gans

INVOICE

54523

DATE

10-8-22





PATIENT

Eeyore Collins

SPECIES

Canine

BREED

Labrador Retriever
Mix

SEX

Male

AGE

9 Years

INTERPRETED BY

Nele Eley, DVM
Dr. med. Vet. DipECVDI

HOSPITAL NAME

Scottsdale Veterinary
Clinic

REFERRING VET

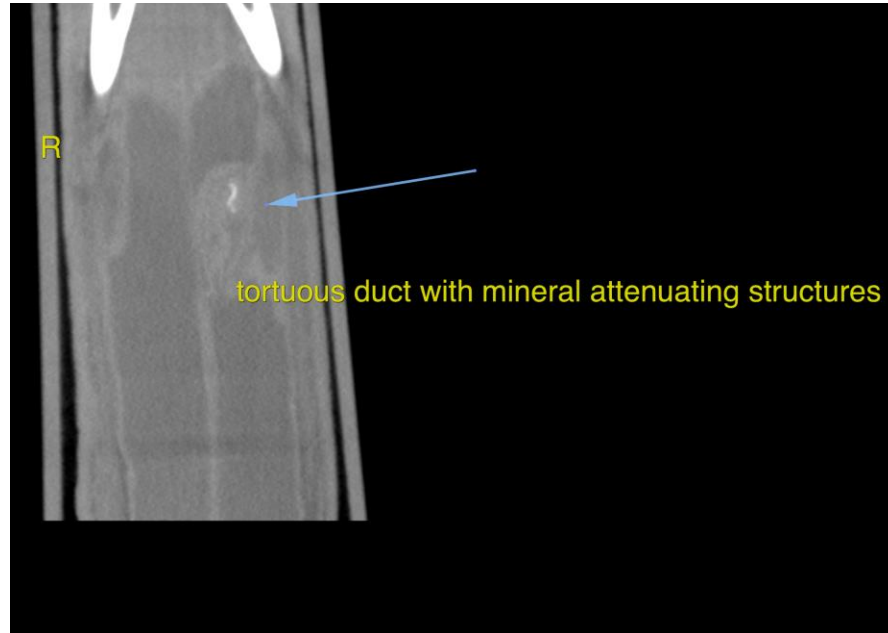
Dr. Gans

INVOICE

54523

DATE

10-8-22



The information and recommendations provided are based on the images presented by the referring veterinarian/sonographer. No evaluation can be communicated regarding pathology that was not visible in the image/video clips provided.

Thank you for this referral. If the clinical or image interpretation does not parallel your findings or if I can be of any further assistance please contact me.

Nele Eley, DVM, Dr. med. vet., DipECVDI
European Specialist in Veterinary Diagnostic Imaging, Cert. Radiology,
Senior lecturer University of Giessen, Germany, Veterinary Faculty, Department of Radiology
Nele.Eley@sonopath.com