

**PATIENT**

Summer Hilary

PRESENTING CLINICAL SIGNS

Competition show dog with chronic persistent RHL skipping gait. I have been unsuccessful in locating the source of discomfort, and rehabilitation therapy has yielded similarly disappointing results.

SPECIES

Canine

ULTRASONOGRAPHIC FINDINGS

Both iliopsoas tendons present thin and smoothly delineated with regular echogenic fiber pattern. The attachment to the lesser trochanter is smooth. The tendon blends smoothly into the muscular tissue. Muscle volume and echoarchitecture present within normal limits. The surrounding soft tissues present within normal limits.

BREED

Cocker Spaniel

The peroneus and tibialis portions of the peripheral sciatic nerve were scanned distal from the trochanteric fossa and reveal no deviation from their expected ultrasonographic anatomy.

SEX

F

Both coxofemoral joints present no deviation from their expected anatomy.

AGE

3 Years

ULTRASONOGRAPHIC DIAGNOSIS

- Structurally normal iliopsoas muscle / psoas major tendon in both hind limbs.

INTERPRETATION OF THE FINDINGS & FURTHER RECOMMENDATIONS

The ultrasonographic study of the caudal muscular portion of the iliopsoas and psoas major tendon is within normal limits. Micro-fiber damage, as in stage 1 musculotendinopathy, cannot be ruled out based on ultrasound; however, there is no macromorphological evidence of iliopsoas injury in either of the hind limbs at this point.

INTERPRETED BY

Nele Eley, DVM
Dr. med. Vet. DipECVDI

HOSPITAL NAME

Points East West
Veterinary Services

REFERRING VET

David Lane

INVOICE

47737

DATE

10-8-21



PATIENT

Summer Hilary

SPECIES

Canine

BREED

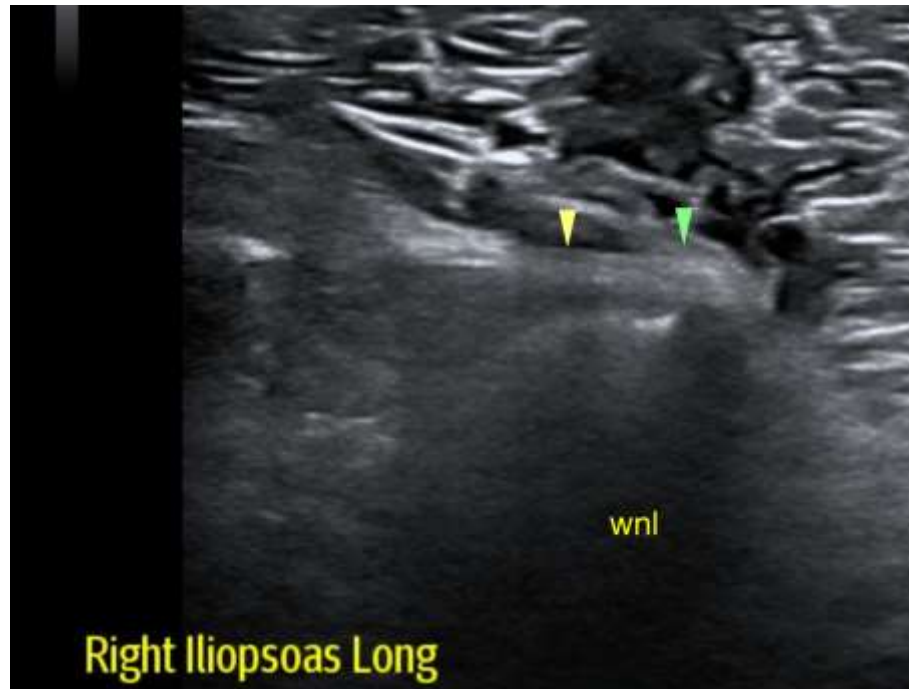
Cocker Spaniel

SEX

F

AGE

3 Years



Right Iliopsoas Long

INTERPRETED BY

Nele Eley, DVM
Dr. med. Vet. DipECVDI

The information and recommendations provided are based on the images presented by the referring veterinarian. No evaluation can be communicated regarding pathology that was not visible in the image/video clips provided.

Thank you for this referral. If the clinical or image interpretation does not parallel your findings or if I can be of any further assistance please contact me.

HOSPITAL NAME

Points East West
Veterinary Services

Nele Eley, DVM, Dr. med. vet., DipECVDI
European Specialist in Veterinary Diagnostic Imaging, Cert. Radiology,
Senior lecturer University of Giessen, Germany, Veterinary Faculty, Department of Radiology
Nele.Eley@sonopath.com

REFERRING VET

David Lane

INVOICE

47737

DATE

10-8-21