



**PATIENT**

Snowi Pancir

**PRESENTING CLINICAL SIGNS**

mass of rostral mandible consistent with SCC on previous histopathology

**SPECIES**

Canine

**COMPUTED TOMOGRAPHIC STUDY OF THE ABDOMEN**

Plain study only available for review.

**BREED**

Beagle

**COMPUTED TOMOGRAPHIC FINDINGS**

The collimated field of view does not contain the entire abdomen. Part of the liver, spleen, urinary bladder, right kidney, and intestine are not included.

**SEX**

FS

A moderate amount of mineral attenuating material can be seen in a curvilinear arrangement in the position of the gallbladder. The remainder of the liver presents moderate generalized enlargement with rounded lobar margins. No solid mass lesion is identified; however, the assessment is limited to the availability of a plain study and not all of the liver is included.

The stomach, pancreas, visible portions of the kidneys, adrenal glands, and intestine present within the expected limits.

**AGE**

11 Years

**COMPUTED TOMOGRAPHIC DIAGNOSIS**

- Suspect gallbladder sand / gallbladder wall mineralization.
- No liver mass seen.

**INTERPRETED BY**

Nele Eley, DVM  
Dr. med. Vet. DipECVDI

**INTERPRETATION OF THE FINDINGS & FURTHER RECOMMENDATIONS**

Limited study. If available, please submit post-contrast study of the abdomen to complement the plain series.

**HOSPITAL NAME**

Animal Surgical  
Center

I do suspect the mineral attenuating material to be contained within the anatomic limits gallbladder in terms of gallbladder sand and/or mineralization of the gallbladder wall, which may be associated with delayed gallbladder emptying, intermittent passage of small calculi/sand, and/or cholecystitis.

A solid liver mass was not seen; however, the assessment is limited.

**REFERRING VET**

North Shore Vet  
Hospital

**INVOICE**

47760

**DATE**

10-7-21



**PATIENT**

Snowi Pancir

**SPECIES**

Canine

**BREED**

Beagle

**SEX**

FS

**AGE**

11 Years

**INTERPRETED BY**

Nele Eley, DVM  
Dr. med. Vet. DipECVDI

**HOSPITAL NAME**

Animal Surgical  
Center

**REFERRING VET**

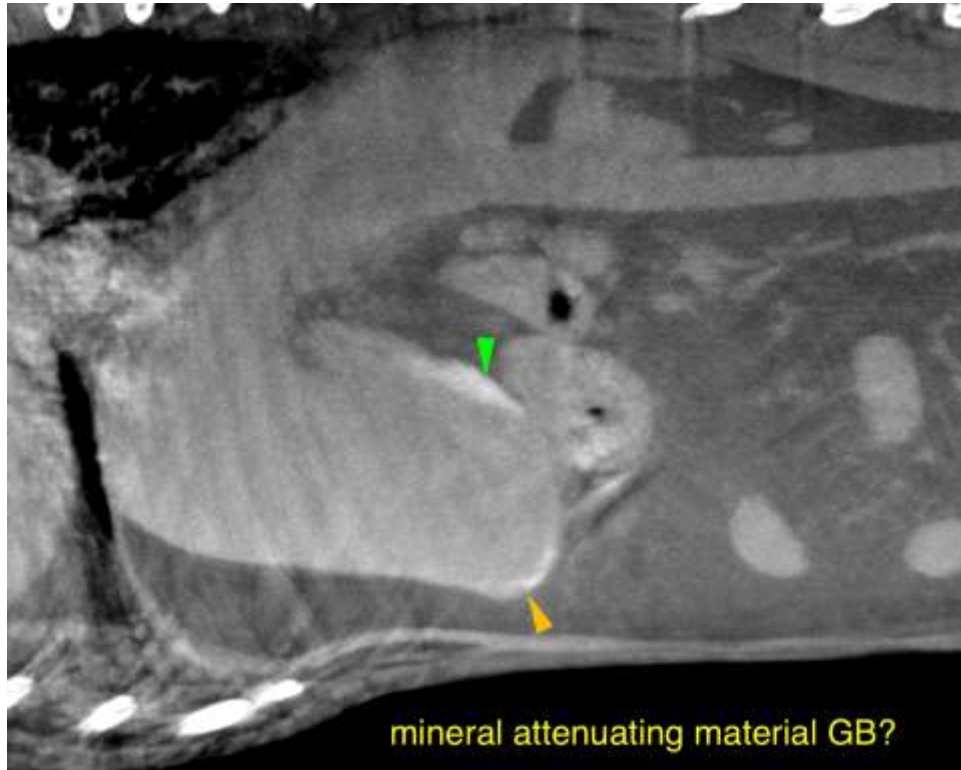
North Shore Vet  
Hospital

**INVOICE**

47760

**DATE**

10-7-21



The information and recommendations provided are based on the images presented by the referring veterinarian. No evaluation can be communicated regarding pathology that was not visible in the image/video clips provided.

Thank you for this referral. If the clinical or image interpretation does not parallel your findings or if I can be of any further assistance please contact me.

**Nele Eley**, DVM, Dr. med. vet., DipECVDI  
European Specialist in Veterinary Diagnostic Imaging, Cert. Radiology,  
Senior lecturer University of Giessen, Germany, Veterinary Faculty, Department of Radiology  
Nele.Eley@sonopath.com