

**PATIENT**

Ace Heyen

PRESENTING CLINICAL SIGNS

2 weeks ago had accident at home where hit glass window, checked and cleared of concussion next day, last weekend taken to emergency vets as disorientated, collapsing and not eating well - lost 2kg since accident. bloods normal, has improved slightly but still wobbly

SPECIES

Canine

COMPUTED TOMOGRAPHIC STUDY OF THE BRAIN

Plain and post contrast studies available for review.

BREED

Greyhound

COMPUTED TOMOGRAPHIC FINDINGS

A large round cystic suprasellar mass is seen in the ventral midline. The mass is well delineated and presents peripheral rim enhancement with fluid attenuating contrast negative center. The diameter of the mass is approximately 18mm. Severe extension beyond sella turcica is seen with severe dorsal displacement of the interthalamic adhesion and compression of the third ventricle as well as caudodorsal displacement of the thalamus and hypothalamus. No bone lysis and no hyperostosis is seen in the underlying skull base.

SEX

Male

COMPUTED TOMOGRAPHIC DIAGNOSIS

- Large cystic suprasellar mass with severe mass effect onto thalamus and hypothalamus.

AGE

8 Years

INTERPRETATION OF THE FINDINGS & FURTHER RECOMMENDATIONS**INTERPRETED BY**

Nele Eley, DVM
Dr. med. Vet. DipECVDI

The CT study reveals a large cystic suprasellar mass with severe mass effect. Increased intracranial pressure has to be assumed. At this point, no obstructive hydrocephalus is seen, and no cerebellar herniation can be recognized yet the mass effect appears to be severe. Owing to the cystic appearance, differential diagnosis includes Rathke's cyst as well as cystic neoplasia such as cystic meningioma, cystic adenoma, or cystic adenocarcinoma. Abscess and hematoma with pituitary apoplexy are considered by far less likely but cannot be ruled out entirely.

HOSPITAL NAME

Adelaide Plains
Veterinary Surgery

REFERRING VET

John Katakasi

INVOICE

47729

DATE

10-7-21



PATIENT

Ace Heyen

SPECIES

Canine

BREED

Greyhound

SEX

Male

AGE

8 Years

INTERPRETED BY

Nele Eley, DVM
Dr. med. Vet. DipECVDI

HOSPITAL NAME

Adelaide Plains
Veterinary Surgery

REFERRING VET

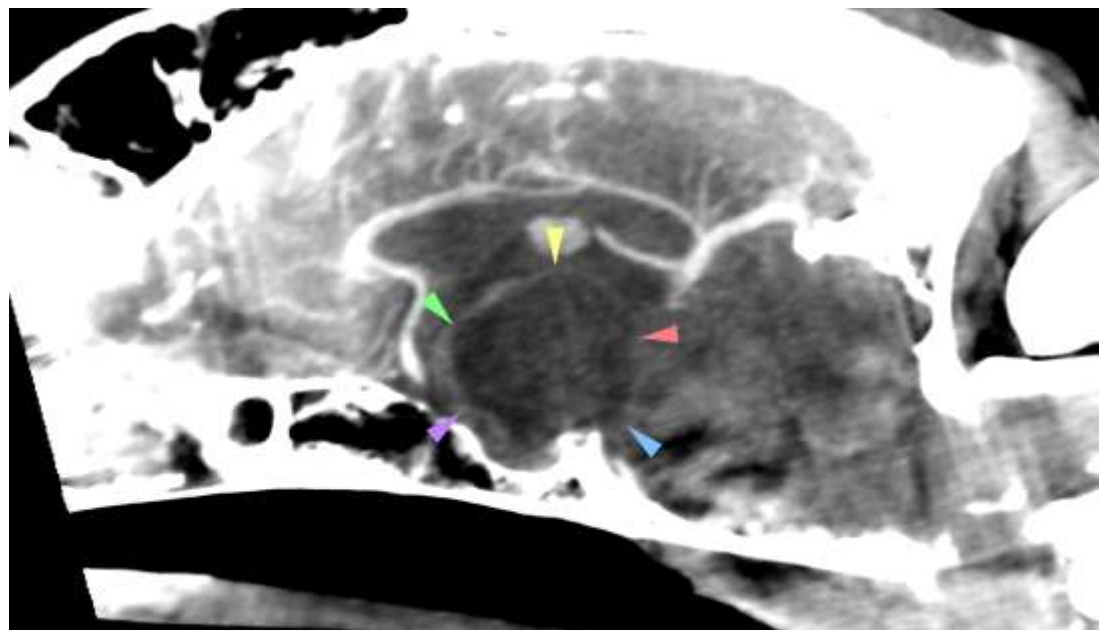
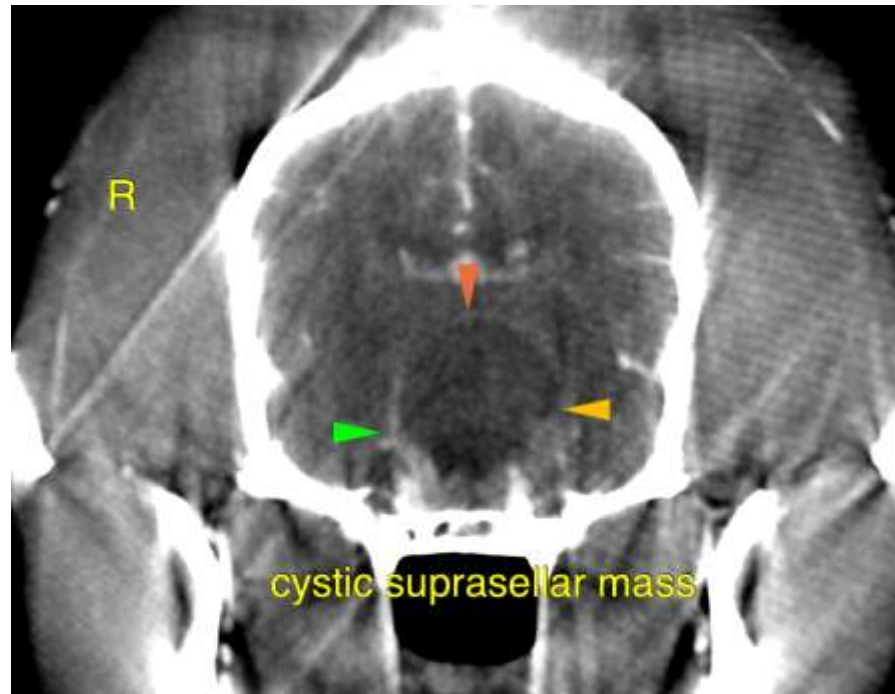
John Katakasi

INVOICE

47729

DATE

10-7-21





PATIENT

Ace Heyen

The information and recommendations provided are based on the images presented by the referring veterinarian. No evaluation can be communicated regarding pathology that was not visible in the image/video clips provided.

Thank you for this referral. If the clinical or image interpretation does not parallel your findings or if I can be of any further assistance please contact me.

SPECIES

Canine

Nele Eley, DVM, Dr. med. vet., DipECVDI
European Specialist in Veterinary Diagnostic Imaging, Cert. Radiology,
Senior lecturer University of Giessen, Germany, Veterinary Faculty, Department of Radiology
Nele.Eley@sonopath.com

BREED

Greyhound

SEX

Male

AGE

8 Years

INTERPRETED BY

Nele Eley, DVM
Dr. med. Vet. DipECVDI

HOSPITAL NAME

Adelaide Plains
Veterinary Surgery

REFERRING VET

John Katakasi

INVOICE

47729

DATE

10-7-21