



PATIENT PRESENTING CLINICAL SIGNS

PATIENT Elvis Evje
SPECIES Canine
BREED Bloodhound

O was out of town for a little over a week and Elvis was being watched by family. He ate during that time but wasn't as playful. O got back on Saturday. He ate that night but didn't finish his food which isn't too unusual for him. The night before last he didn't touch his food at all. O took him to Bluepearl last night. They said he had a tooth infection and has some dental problems. O took him to Riverside today and they said there could be a possible retrobulbar abscess behind his R eye. His eye wasn't swollen/red until this morning, it was relatively normal prior. When he went to open his mouth for a piece of chicken he cried. O looked in his mouth and once O opened his mouth he would howl and cry in pain and shake. He did vomit last night when O gave him his antibiotics - he wouldn't eat anything offered. No c/s/d. Problem List - severe dental calculus and tartar, painful mouth - OD swelling, elevated third eyelid - Vomited x 1 - Hyporexia Concerned for retrobulbar mass/abscess.

COMPUTED TOMOGRAPHIC STUDY OF THE HEAD

SEX Plain and post contrast studies available for review.

M

COMPUTED TOMOGRAPHIC FINDINGS

AGE 8 Years

An approximately 3.5 x 2.0 cm sized hypoattenuating lesion with mass effect and peripheral rim enhancement and contrast negative center is seen in the right retrobulbar space. Peripheral soft tissue swelling, increased attenuation of the orbital fat, and retromolar soft tissue swelling are seen concurrently. There is moderate right sided exophthalmos. The lesion cannot be delineated from the zygomatic gland and medial pterygoid muscle.

INTERPRETED BY

Nele Eley, DVM
 Dr. med. Vet. DipECVDI

The right medial retropharyngeal lymph node is moderately enlarged. Mild enlargement of the right submandibular lymph nodes is noted.

HOSPITAL NAME

Mountain West
 Veterinary Hospital

Conformation of both external auditory meatuses is narrow. Moderate thickening of their epithelial lining and a moderate amount of hypoattenuating luminal material is noted. The tympanic bullae present within normal limits.

The teeth present multifocal mild periodontal changes with moderate horizontal atrophy of the alveolar crest in both maxillary quadrants. No evidence of tooth root abscessation is seen.

REFERRING VET

Naomi Guzman

COMPUTED TOMOGRAPHIC DIAGNOSIS

- Cavitory lesion within the right orbita with extensive peripheral soft tissue swelling and exophthalmos.
- Right sided medial retropharyngeal and submandibular lymphadenomegaly.
- Periodontal disease with no evidence of tooth root abscessation.
- Bilateral otitis externa.

INVOICE

54502

INTERPRETATION OF THE FINDINGS & FURTHER RECOMMENDATIONS

DATE

10-6-22

The CT findings are suggestive for a retrobulbar abscess. Tumor with central tumoral necrosis and zygomatic sialocele are theoretical but less likely differential diagnoses. Foreign material is not seen.

The lymph node changes are compatible with reactive hyperplasia. Metastatic diseases cannot be



PATIENT ruled out entirely but is thought less likely.

Elvis Eyje No dental changes that would be relevant to the orbital disease are identified.

SPECIES Consider the presumed abscess drainage with sampling for culture and histology as well as fine needle aspiration of the right retropharyngeal and submandibular lymph nodes. Dental workup and further otoscopic workup could be considered as well.

Canine

BREED

Bloodhound

SEX

M

AGE

8 Years

INTERPRETED BY

Nele Eley, DVM
Dr. med. Vet. DipECVDI

HOSPITAL NAME

Mountain West
Veterinary Hospital

REFERRING VET

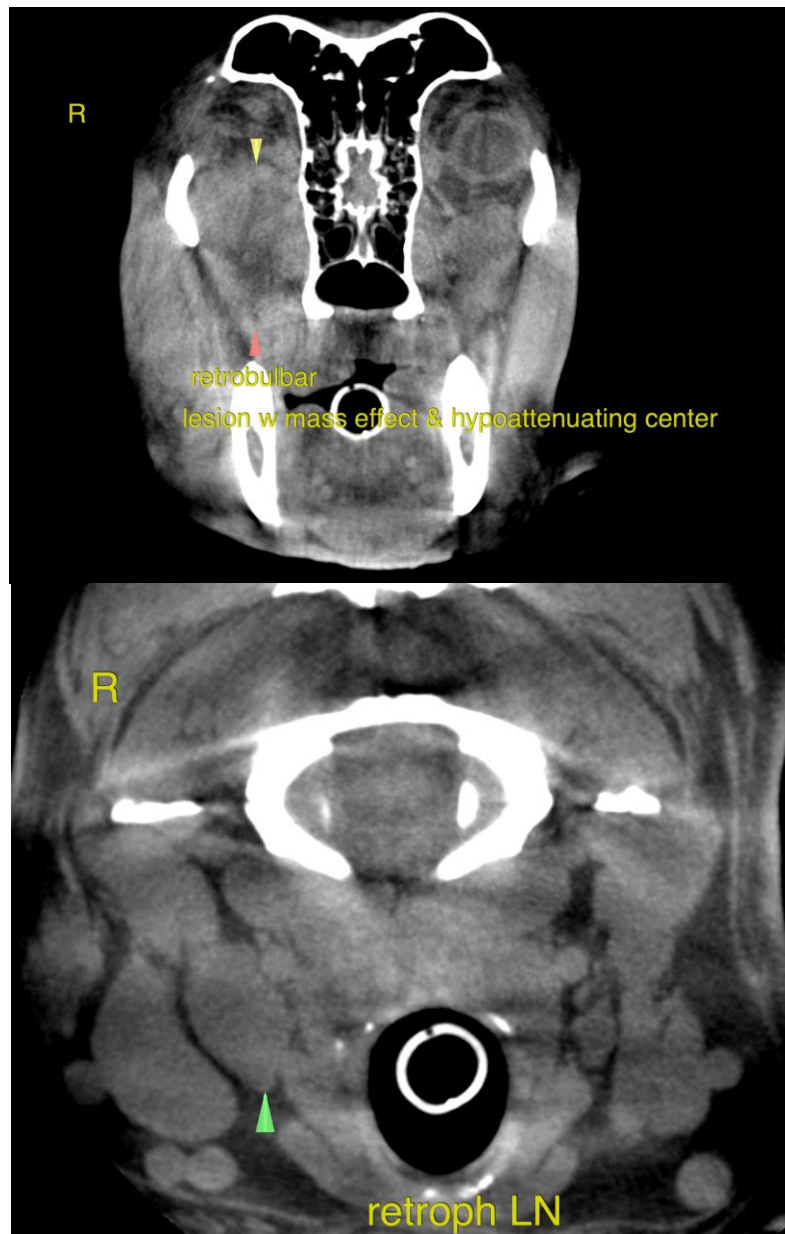
Naomi Guzman

INVOICE

54502

DATE

10-6-22





PATIENT

Elvis Evje

The information and recommendations provided are based on the images presented by the referring veterinarian/sonographer. No evaluation can be communicated regarding pathology that was not visible in the image/video clips provided.

SPECIES

Canine

Thank you for this referral. If the clinical or image interpretation does not parallel your findings or if I can be of any further assistance please contact me.

BREED

Bloodhound

Nele Eley, DVM, Dr. med. vet., DipECVDI
European Specialist in Veterinary Diagnostic Imaging, Cert. Radiology,
Senior lecturer University of Giessen, Germany, Veterinary Faculty, Department of Radiology
Nele.Eley@sonopath.com

SEX

M

AGE

8 Years

INTERPRETED BY

Nele Eley, DVM
Dr. med. Vet. DipECVDI

HOSPITAL NAME

Mountain West
Veterinary Hospital

REFERRING VET

Naomi Guzman

INVOICE

54502

DATE

10-6-22