

**PATIENT**

Walter Lenz

PRESENTING CLINICAL SIGNS

Mets check

SPECIES

Canine

COMPUTED TOMOGRAPHIC STUDY OF THE THORAX

Plain study available for review.

BREED

Labrador Retriever

COMPUTED TOMOGRAPHIC FINDINGS

The lungs are not fully included. The caudal and lateral portions of the caudal lung lobes are outside the field of view. All the lung that is inside the field of view presents within age related normal limits. No evidence of interstitial nodules is seen.

SEX

Male Neutered

There are occasional age related and incidental pulmonary osteomas. Mild multifocal peribronchial interstitial infiltrates with ground glass opacity are seen. There are minimal atelectatic changes.

The caudocervical trachea presents mild dorsoventral collapse.

AGE

11 Years, 8 Months

One sternal lymph node is mildly enlarged and measures 16mm x 12mm.

INTERPRETED BYNele Eley, DVM
Dr. med. Vet. DipECVDI

- Limited study.
- No evidence of pulmonary metastatic disease.
- Caudocervical tracheal collapse.
- Mild sternal lymphadenomegaly.

INTERPRETATION OF THE FINDINGS & FURTHER RECOMMENDATIONS

As far as included, there is no evidence of pulmonary metastatic disease. All noted pulmonary changes are considered within age related normal limits and/or related to general anesthesia.

Differential diagnosis for the sternal lymphadenomegaly includes reactive hyperplasia as well as neoplastic infiltrate/metastatic disease. Consider ultrasound guided fine needle aspiration for further definition.

HOSPITAL NAMEState Avenue Vet
Clinic**REFERRING VET**

Dr. Raul Casas-Dolz

INVOICE

47702

DATE

10-6-21



PATIENT

Walter Lenz

SPECIES

Canine

BREED

Labrador Retriever

SEX

Male Neutered

AGE

11 Years, 8 Months

INTERPRETED BY

Nele Eley, DVM
Dr. med. Vet. DipECVDI

HOSPITAL NAME

State Avenue Vet
Clinic

REFERRING VET

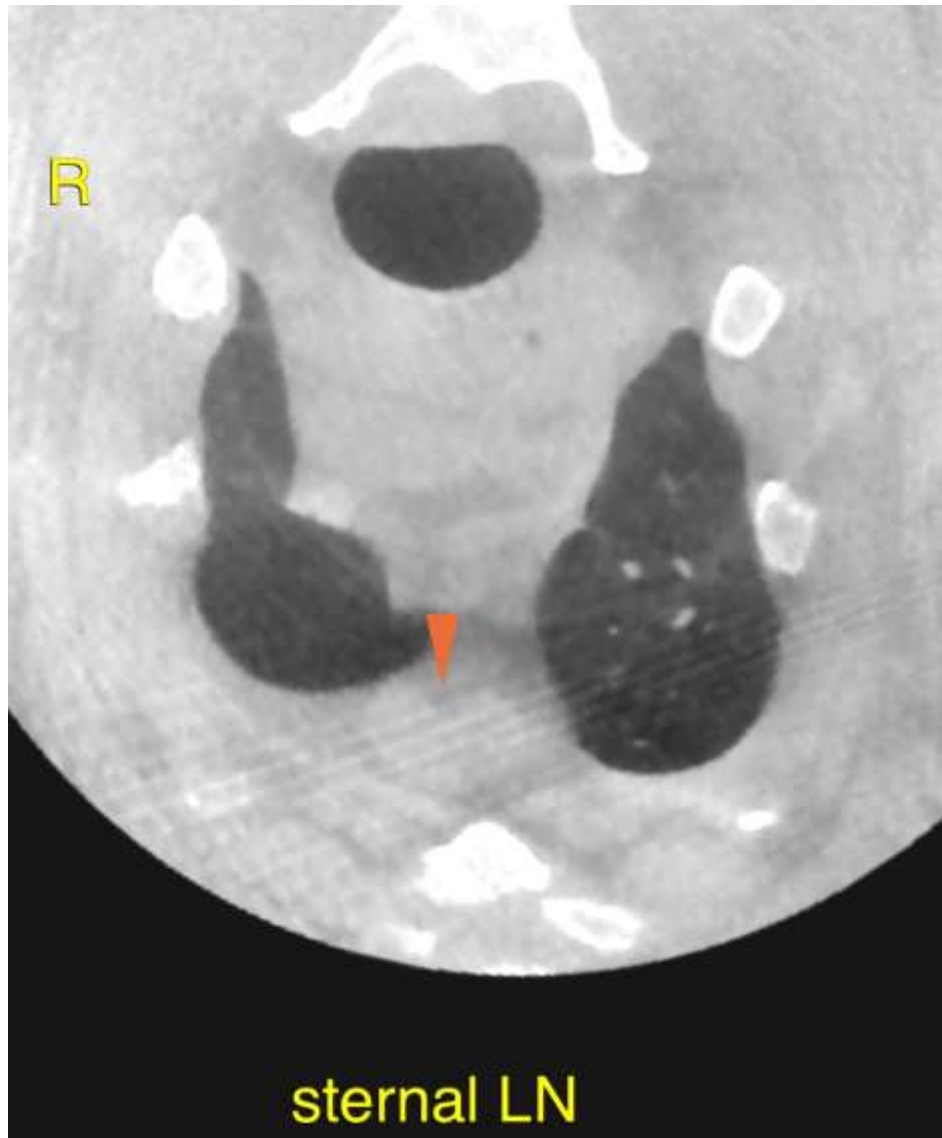Dr. Raul Casas-Dolz

INVOICE

47702

DATE

10-6-21





PATIENT

Walter Lenz

SPECIES

Canine

BREED

Labrador Retriever

SEX

Male Neutered

AGE

11 Years, 8 Months

INTERPRETED BY

Nele Eley, DVM
Dr. med. Vet. DipECVDI

HOSPITAL NAME

State Avenue Vet
Clinic

REFERRING VET

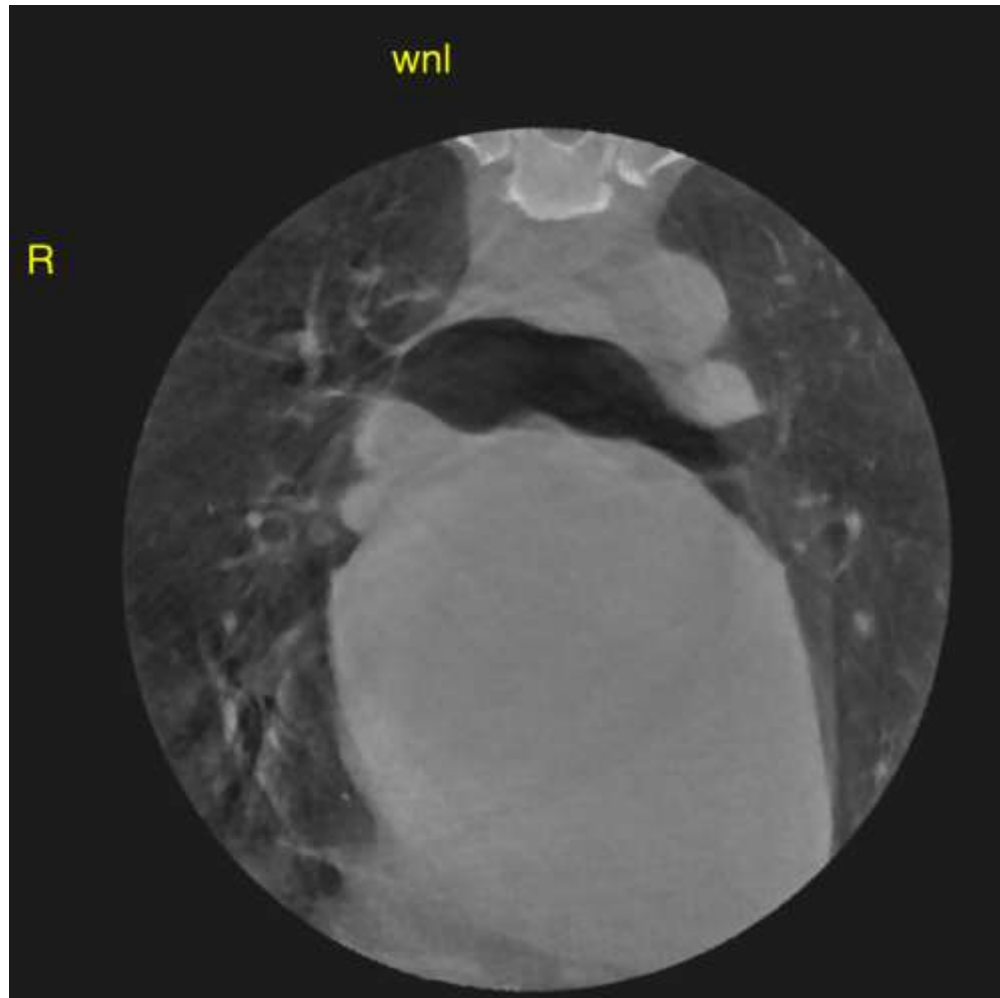
Dr. Raul Casas-Dolz

INVOICE

47702

DATE

10-6-21



The information and recommendations provided are based on the images presented by the referring veterinarian. No evaluation can be communicated regarding pathology that was not visible in the image/video clips provided.

Thank you for this referral. If the clinical or image interpretation does not parallel your findings or if I can be of any further assistance please contact me.

Nele Eley, DVM, Dr. med. vet., DipECVDI
European Specialist in Veterinary Diagnostic Imaging, Cert. Radiology,
Senior lecturer University of Giessen, Germany, Veterinary Faculty, Department of Radiology
Nele.Eley@sonopath.com