SonoPath Teleradiology

EDUCATIONAL TELECONSULTATION SERVICES™

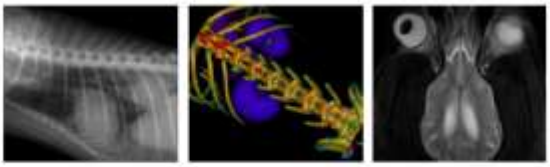

SonoPath.com
1-800-838-4268 info@sonopath.com

PATIENT

Mickey Damours

SPECIES

Feline

BREED

DSH

SEX

Male Neuter

AGE

2 Years, 6 Months

INTERPRETED BY

Nele Eley, DVM
Dr. med. Vet. DipECVDI

HOSPITAL NAME

Blandford Animal Hospital

REFERRING VET

Amber Cull-Fournier

INVOICE

47697

DATE

10-6-21

PRESENTING CLINICAL SIGNS

intermittent coughing since adopted from cat rescue in 2020, improved with prednisolone, frequency seems to increase when owner's allergies increase, cat is hunter,
Abnormal PE/Chem/CBC/UA Results: obese cat, lungs slightly harsh caudally with no increase to respiratory effort and no wheezing

RADIOGRAPHIC STUDY OF THE THORAX

Right/left lateral and ventrodorsal views totaling 3 images available for review.

RADIOGRAPHIC FINDINGS

Mild esophageal aerophagia is noted.

The lungs are moderately inflated. A moderate bronchial lung pattern with caudodorsal accentuation is seen. Mild peribronchial cuffing is present concurrently.

There is no evidence of mediastinal widening.

The cardiovascular structures present within normal limits.

The thoracic boundaries present within normal limits as well.

RADIOGRAPHIC DIAGNOSIS

- Moderate active lower airway pattern with caudodorsal accentuation.
- Mild esophageal aerophagia - incidental.

INTERPRETATION OF THE FINDINGS & FURTHER RECOMMENDATIONS

The radiographic findings support the presence of chronic active lower airway disease. Allergic feline lower airway syndrome appears most likely, synthesizing the clinical history and radiographic findings. However, irritant and infectious bronchitis such as viral, bacterial, parasitic, or protozoal cannot be ruled out entirely.

SonoPath Teleradiology

EDUCATIONAL TELECONSULTATION SERVICES™

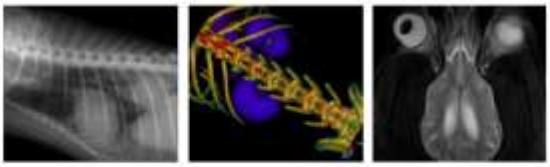

SonoPath.com
1-800-838-4268 info@sonopath.com

PATIENT

Mickey Damours

SPECIES

Feline

BREED

DSH

SEX

Male Neuter

AGE

2 Years, 6 Months

INTERPRETED BY

Nele Eley, DVM
Dr. med. Vet. DipECVDI

HOSPITAL NAME

Blandford Animal Hospital

REFERRING VET

Amber Cull-Fournier

INVOICE

47697

DATE

10-6-21

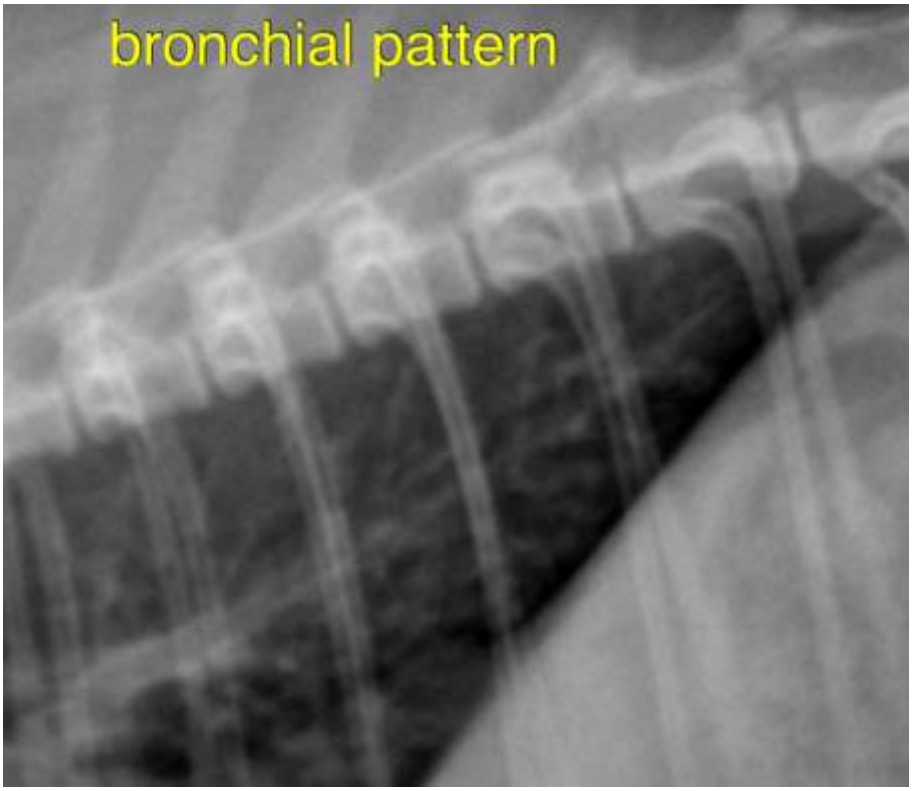

The information and recommendations provided are based on the images presented by the referring veterinarian. No evaluation can be communicated regarding pathology that was not visible in the image/video clips provided.

Thank you for this referral. If the clinical or image interpretation does not parallel your findings or if I can be of any further assistance please contact me.

Nele Eley, DVM, Dr. med. vet., DipECVDI
European Specialist in Veterinary Diagnostic Imaging, Cert. Radiology,
Senior lecturer University of Giessen, Germany, Veterinary Faculty, Department of Radiology
Nele.Eley@sonopath.com