



PATIENT

Remy Mancini

PRESENTING CLINICAL SIGNS

Pt presented for limping on left hind leg that has been going on for about a month and a half on/off. O reports pt had hip surgery on left hind from being hit by a car previously. On PE: no lameness noted, thickening of medial aspect of left stifle, rt hip made popping sound when extending for VD.

SPECIES

Canine

RADIOGRAPHIC STUDY OF THE STIFLES

Mediolateral and craniocaudal views of both stifles totaling 4 images available for review.

BREED

Pitbull Mix

RADIOGRAPHIC FINDINGS

Patient has a history of right femoral head ostectomy.

SEX

SF

Moderate articular swelling of the left stifle joint is seen. Significant thrust of the tibia cannot be identified in the available radiographs. Mild periarticular osteophytes accentuating the femoral trochlea, cranial margin of the tibial plateau, and distal pole of the patella are seen.

No significant muscle atrophy is noted in the hind limbs.

AGE

7 Years

The hip joints are not part of the read however the left hip joint presents moderate coxofemoral joint dysplasia and osteoarthritis.

The right stifle joint presents within normal age related limits.

INTERPRETED BY

Nele Eley, DVM
Dr. med. Vet. DipECVDI

RADIOGRAPHIC DIAGNOSIS

- Moderate left stifle osteoarthritis with articular swelling and osteophytosis.

HOSPITAL NAME

The Pet Hospital of
Stratford

INTERPRETATION OF THE FINDINGS & FURTHER RECOMMENDATIONS

The left stifle joint presents moderate osteoarthritic changes. Cranial cruciate ligament pathology and meniscopathy are the most common underlying causes. Other arthropathy including arthritis cannot be ruled out entirely even though by far less common and less likely to correlate with the clinical palpation. MRI and/or arthroscopy as well as aspiration and analysis of synovia could be discussed as potential next steps in the further workup depending on the clinical context.

REFERRING VET

Dr. Giuliani

INVOICE

54461

DATE

10-5-22



PATIENT

Remy Mancini

SPECIES

Canine

BREED

Pitbull Mix

SEX

SF

AGE

7 Years

INTERPRETED BY

Nele Eley, DVM
Dr. med. Vet. DipECVDI

HOSPITAL NAME

The Pet Hospital of
Stratford

REFERRING VET

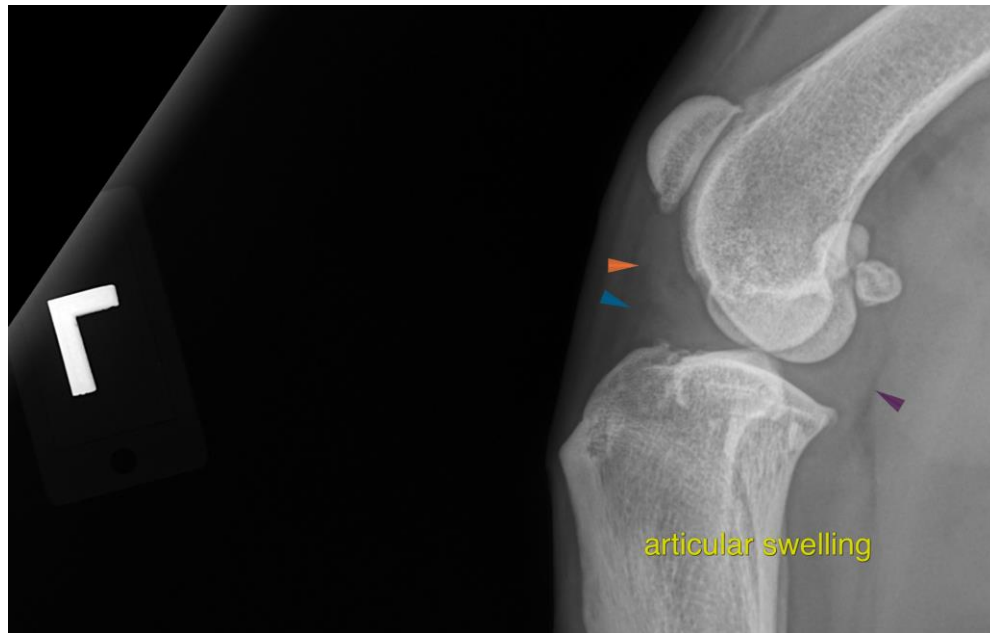
Dr. Giuliani

INVOICE

54461

DATE

10-5-22



The information and recommendations provided are based on the images presented by the referring veterinarian/sonographer. No evaluation can be communicated regarding pathology that was not visible in the image/video clips provided.

Thank you for this referral. If the clinical or image interpretation does not parallel your findings or if I can be of any further assistance please contact me.

Nele Eley, DVM, Dr. med. vet., DipECVDI
European Specialist in Veterinary Diagnostic Imaging, Cert. Radiology,
Senior lecturer University of Giessen, Germany, Veterinary Faculty, Department of Radiology
Nele.Eley@sonopath.com