



PATIENT

Jackson Devries

SPECIES

Feline

BREED

DSH

SEX

Male Neutered

AGE

7 Years

INTERPRETED BY

Nele Eley, DVM
Dr. med. Vet. DipECVDI

HOSPITAL NAME

Northshore
Veterinary Hospital

REFERRING VET

Janiene Licciardi

INVOICE

54467

DATE

10-5-22

PRESENTING CLINICAL SIGNS

Jackson presented today with increased lethargy and a one-time episode of "swaying" as if about to collapse or lose consciousness. This episode occurred one month ago. On exam, Jackson has a very loud heart murmur (4/6 systolic) and increased respiratory sounds/ crackles, with mildly increased respiratory effort. He also appeared nauseous- licking his lips, extending his neck. Vomiting is not part of his history. Exercise intolerance, panting, and coughing are also not part of his history. We first noticed the heart murmur in 2021, called 4/6 at that time also. Abnormal PE/Chem/CBC/UA Results: labs declined by owner

RADIOGRAPHIC STUDY OF THE THORAX

Right/left lateral and ventrodorsal views of the thorax totaling 3 images available for review.

RADIOGRAPHIC FINDINGS

The lungs are deeply inflated. The ribcage is expanded.

Moderate left sided cardiomegaly is seen with moderate basico-apical enlargement of the cardiac silhouette as well as left atrial enlargement and a vascular lung pattern accentuating the perihilar region of the lung. The vertebral heart score is 9.5; reference range up to 8.5.

Moderate gastrointestinal aerophagia is noted.

There is no evidence of pleural effusion.

RADIOGRAPHIC DIAGNOSIS

- Moderate left sided cardiomegaly with vascular lung pattern suggesting ongoing left sided congestive heart failure.
- Aerophagia – likely secondary to respiratory distress.

INTERPRETATION OF THE FINDINGS & FURTHER RECOMMENDATIONS

The radiographic study reveals left sided cardiomegaly with a vascular lung pattern suggesting ongoing left sided congestive heart failure with emerging cardiogenic pulmonary edema. The enlarged atrium/atria may also predispose to the development of smoke and thrombi. Underlying cardiomyopathy or other cardiac pathology is considered likely. Further definition by means of a full cardiac echo is strongly recommended if possible.



PATIENT

Jackson Devries

SPECIES

Feline

BREED

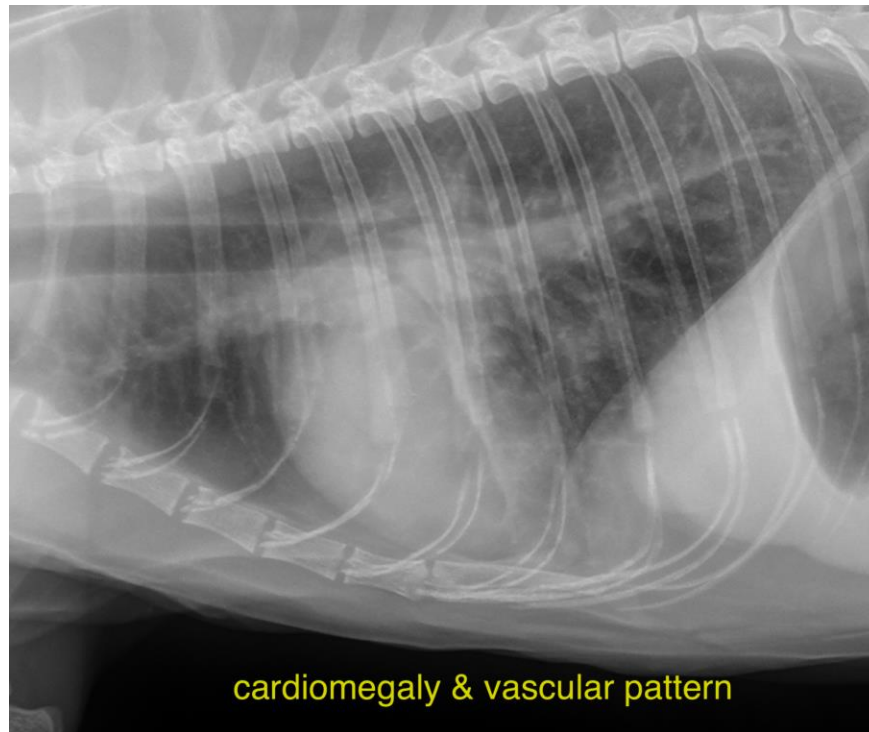
DSH

SEX

Male Neutered

AGE

7 Years



INTERPRETED BY

Nele Eley, DVM
Dr. med. Vet. DipECVDI

The information and recommendations provided are based on the images presented by the referring veterinarian/sonographer. No evaluation can be communicated regarding pathology that was not visible in the image/video clips provided.

HOSPITAL NAME

Northshore
Veterinary Hospital

Thank you for this referral. If the clinical or image interpretation does not parallel your findings or if I can be of any further assistance please contact me.

Nele Eley, DVM, Dr. med. vet., DipECVDI
European Specialist in Veterinary Diagnostic Imaging, Cert. Radiology,
Senior lecturer University of Giessen, Germany, Veterinary Faculty, Department of Radiology
Nele.Eley@sonopath.com

REFERRING VET

Janiene Licciardi

INVOICE

54467

DATE

10-5-22